

11th November, 2022

The General Manager,
Department of Corporate services
Bombay Stock Exchange Ltd (BSE)
Phiroze Jheejheebhoy Towers,
Dalal Street,
Mumbai - 400 001.
Scrip Code - 543308
ISIN: INE967H01017

The Manager,
Listing Department
National Stock Exchange of India Limited,
Exchange Plaza, 5th Floor,
Plot No.C/1, 'G' Block,
Bandra - Kurla Complex,
Mumbai - 400 051.
Symbol - KIMS
ISIN: INE967H01017

Dear Sir,

Sub: Investor presentation – Reg.

Pursuant to Regulation 30 of the Securities and Exchange Board of India (Listing Obligations and Disclosure Requirements) Regulations, 2015 please find enclosed herewith the Investor Presentation on Un-Audited Financial Results of the Company for the Quarter and Half Year ended 30th September 2022.

The said presentation is being uploaded on the website of the Company i.e., <https://www.kimshospitals.com/investors/Disclosures> under Regulation 46 of SEBI (LODR) Regulations, 2015/Analysts Calls schedule, PPT & Transcripts\PPT's.

We request you to take this on record.

Thanking you,
Yours truly,

For Krishna Institute of Medical Sciences Limited

Umashankar Mantha
Company Secretary & Compliance Officer

Krishna Institute of Medical Sciences Limited

Minister Road, Secunderabad - 500 003, Telangana, India
Phone: +91 40 4488 5000/4488 5184 | Fax: +91-40-27840980 | kimshospitals.com
CIN: L55101TG1973PLC040558



MAKING QUALITY
HEALTHCARE
**ACCESSIBLE &
AFFORDABLE**

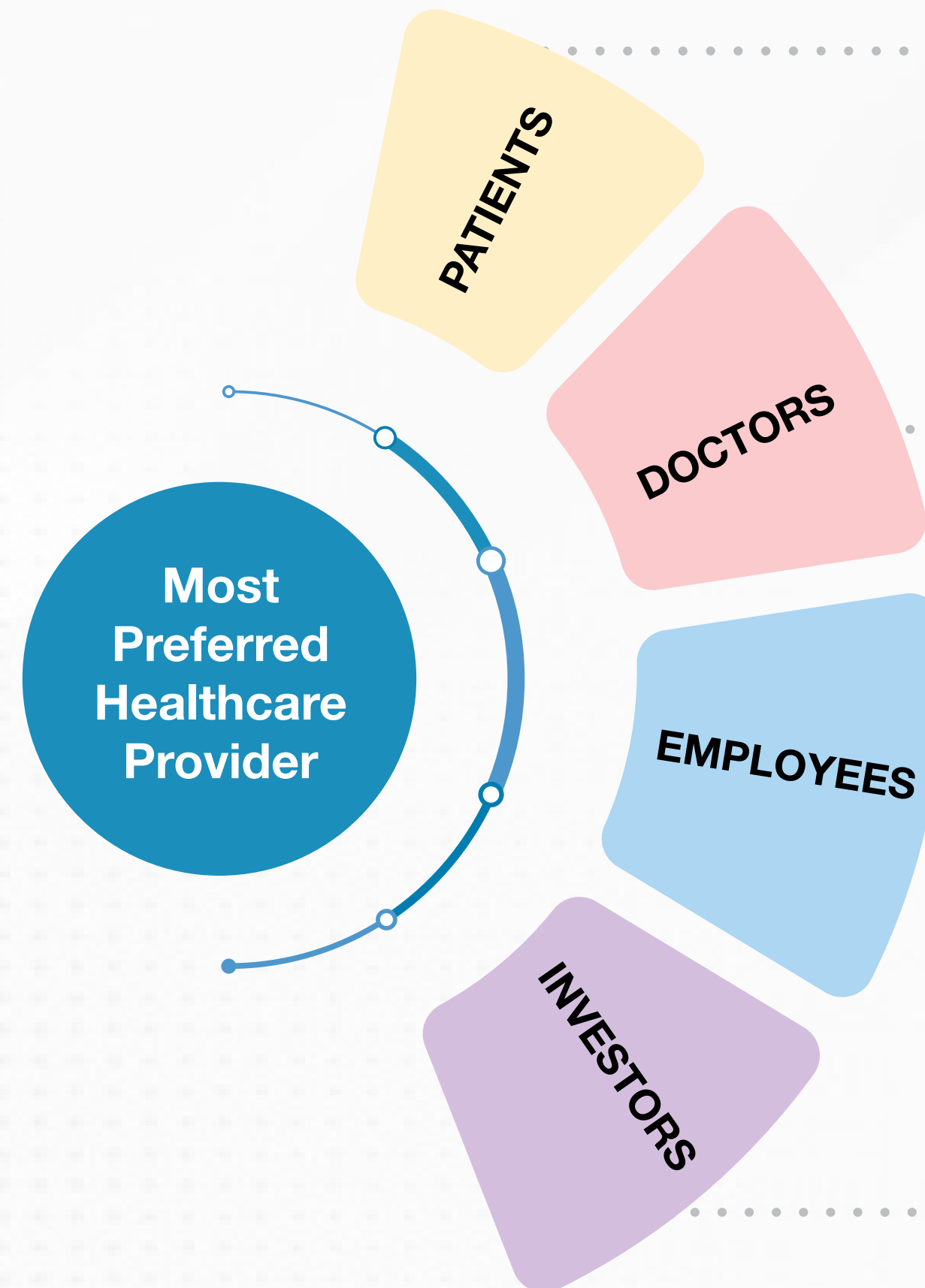
Driven by a Vision

VISION:

To be the most preferred healthcare services brand by providing affordable care and best clinical outcomes to patients.
 And to be the best place to work for doctors and employees.

OUR MISSION:

Provide affordable quality care to our patients with patient-centric systems and processes.
 Enable clinical outcome-driven excellence by engaging modern medical technology.
 Provide a strong impetus for doctors to pursue academics and medical research.



- Affordable Quality Care
- Best-in-Class Facilities
- Patient Centric Systems & Processes

- Clinical Outcome Driven Excellence
- Latest Medical Technology
- Strong Academics & Research Oriented

- Enriching Atmosphere
- Collaborative Culture
- Growth Driven Career Approach

- Transparent Governance
- Strong Operational Performance
- Consistent Growth

Multi Specialty Care

Brain

- Neurology
- Neurosurgery
- Psychiatry
- Neuro Rehabilitation

Heart

- Cardiology
- Cardiac Surgery
- Vascular Surgery
- Heart Transplant
- Cardio Rehabilitation

Lung

- Pulmonology
- Interventional Pulmonology
- Thoracic surgery
- Lung Transplant

ENT

- Ear
- Nose
- Throat
- Head and Neck Surgery

Eyes

- Ophthalmology

Gastro Intestinal Tract

- Medical Gastroenterology
- Surgical Gastroenterology
- Hepatobiliary Pancreatic Surgery

- Liver Transplant

- Bariatric Surgery

Genito Urinary Tract

- Nephrology

- Urology

- Andrology

- Renal Transplant

- Gynecology

- Urogynecology

- IVF and ART

- Fetal Medicine

- Obstetrics

Oncology

- Medical Surgical and Radiation

- BMT and Hematology

Bones and Spine

- Orthopedics
- Arthroscopic Surgery
- Spine Surgery
- Ortho Rehabilitation

Skin

- Dermatology
- Cosmetology
- Plastic and Reconstructive Surgery

Orthodontics

- Maxillo Facial Surgery

Anaesthesia

- OT Anaesthesia
- Day care Anaesthesia
- Pain Medicine

General Specialities

- Internal Medicine
- General Surgery
- Diabetology & Endocrinology

Pediatrics

- Pediatrics & Pediatric Sub Specialities
- Neonatology

Radiology

- Imaging
- Interventional Radiology

Lab Services

- Pathology
- Microbiology
- Biochemistry
- Molecular Biology
- Clinical Hematology

Critical Care Services

- ICU
- CTICU
- SICU
- NICU
- PICU
- Neuro ICU
- ECMO ICU
- Post Transplant ICU

Hospital Infection Control

- Clinical Infectious Diseases

Maharashtra

- Nagpur (334) 📍
- Nashik (Under Construction) 📍

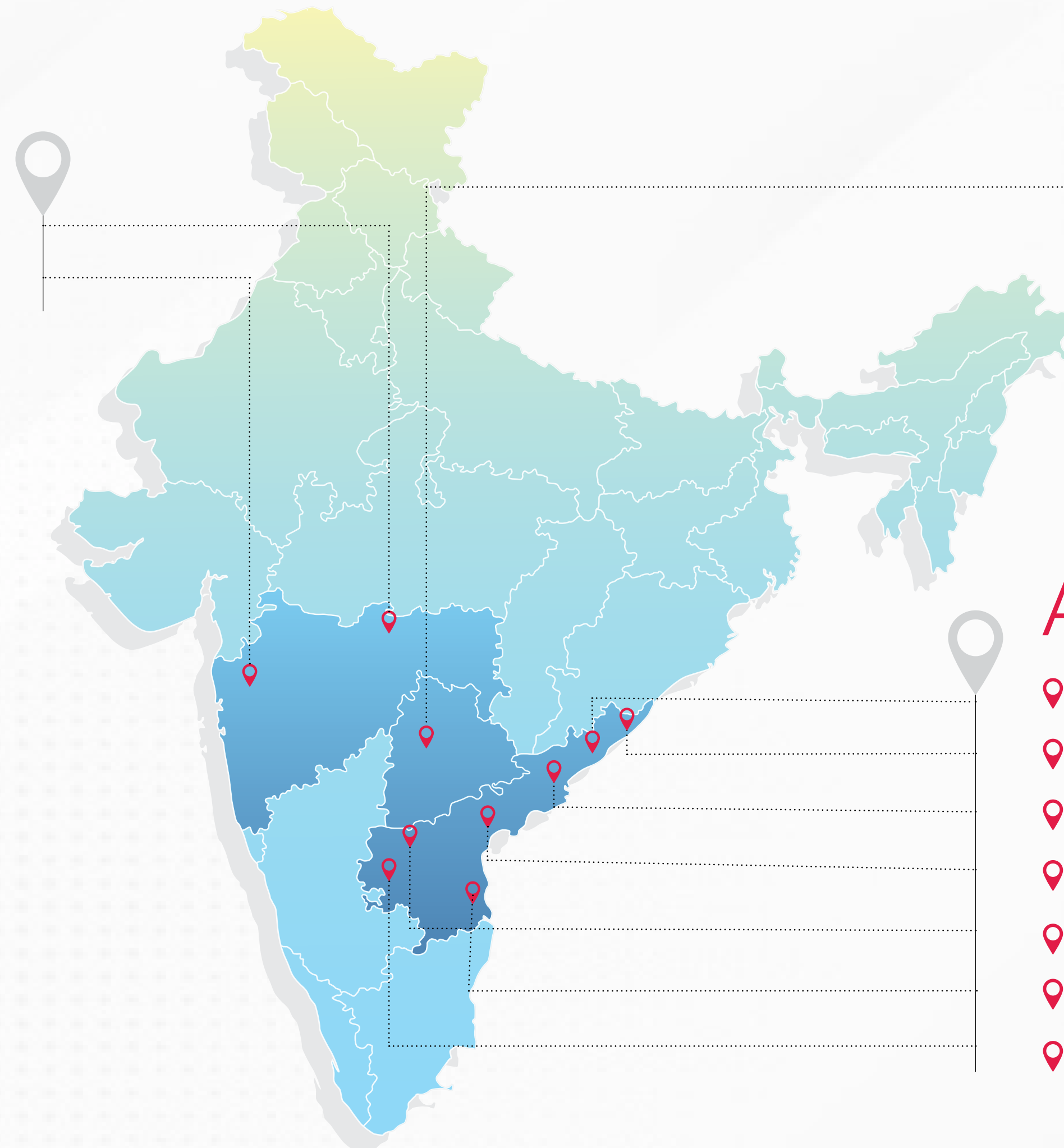
Telangana

- Secunderabad (1000) 📍
- Paradise Circle (290) 📍
- Kondapur (200) 📍
- Gachibowli (237) 📍
- Karimnagar (75) 📍

Andhra Pradesh

- Visakhapatnam (434) 📍
- Srikakulam (200) 📍
- Rajahmundry (195) 📍
- Ongole (350) 📍
- Kurnool (200) 📍
- Nellore (250) 📍
- Anantapur (250) 📍

- BEDS (4,000+)
- DOCTORS (1,607)
- NURSES (3,905)
- PARAMEDICS (2,071)
- ADMIN (6,208)



Dr. B. Bhaskar Rao - Visionary Behind KIMS

Managing Director



A legend in CT Surgery, Dr. Bollineni Bhaskar Rao {MBBS, MS, DNB (CT Surgery)} is one of the very few Cardio-Thoracic Surgeons in the country, who performed over 30000 surgeries in his career spanning over more than 25 years.

Well known in the medical fraternity for his passion towards his profession, Dr. Rao started his entrepreneurial journey at “Mahavir Cardio Vascular Centre” in Hyderabad with 50 beds and performed heart surgeries at an unimaginable low cost of just Rs. 45,000 only. Dr. Rao never turned away any patient from the hospital for want of money.

The brand “Krishna Institute of Medical Sciences”, under Dr. B. Bhaskar Rao’s aegis began its journey in 2004 with a 300 bed hospital on par with the then established hospitals of Hyderabad in professional excellence, the state of art technology and infrastructure facilities.

Today KIMS is spread across 12 locations in Telangana & Andhra Pradesh.

Dr. Bhaskar Rao was instrumental in formulating Rajiv Gandhi Aarogyasri scheme, first time launched in Andhra Pradesh in 2007 for providing health care to the poorest of the poor.

This prestigious scheme has won him accolades from all quarters of the country and the world. He was the chief architect of Aarogyashri scheme for both creating it and implementing it successfully.

This well formulated scheme has become so popular that the other States in India have emulated it time and again.



Dr. Abhinay Bollineni

Chief Executive Officer



Dr. Abhinay Bollineni joined KIMS Hospitals in 2013 and spent the next couple of years in Hospital Operations before taking charge of Strategy & Marketing for the Group in 2015.

In a short span of 5 years, KIMS expanded and opened five additional units (Kondapur, Vizag, Anantapur, Ongole, and Kurnool). Shortly after that, he was appointed as the CEO in 2019. The recent acquisitions led by him were of Sunshine Hospitals, Hyderabad and Kingsway Hospitals, Nagpur.

Dr. B. Abhinay completed MBBS from the Deccan Medical College, Hyderabad, in 2010. He was the lone qualified medical practitioner from India to be selected by the office of Hillary Clinton in 2011, where he participated in the 'International Visitor Leadership Program on Oncology: Research, Prevention and Treatment' held by the US Department of State

He was named in Business World's "BW 40 Under 40" list in 2019.

Under his stewardship, KIMS Hospitals got successfully listed on the Stock Exchanges in India in 2021.

Dr. Abhinay is passionate about using technology to enhance patient experience and clinical care. Towards this, he has spearheaded vital initiatives such as Financial counseling tool which uses AI to help patients with surgery costings among many others

Board of Directors




Dr. Bhaskara Rao Bollineni
Managing Director



Dr. Abhinay Bollineni
Chief Executive Officer



Mrs. Anitha Dandamudi
Whole-time Director



Shantanu Rastogi
Non-Executive Director



Mr. Rajeswara Rao G
Independent Director,
Chairman (Stakeholders'
Relationship Committee)



Mr. Saumen Chakraborty
Independent Director,
Chairman (Audit Committee)



Mr. Pankaj Vaish
Independent Director,
Chairman (Nomination &
Remuneration Committee)



Mr. Venkata Ramudu Jasthi
Independent Director

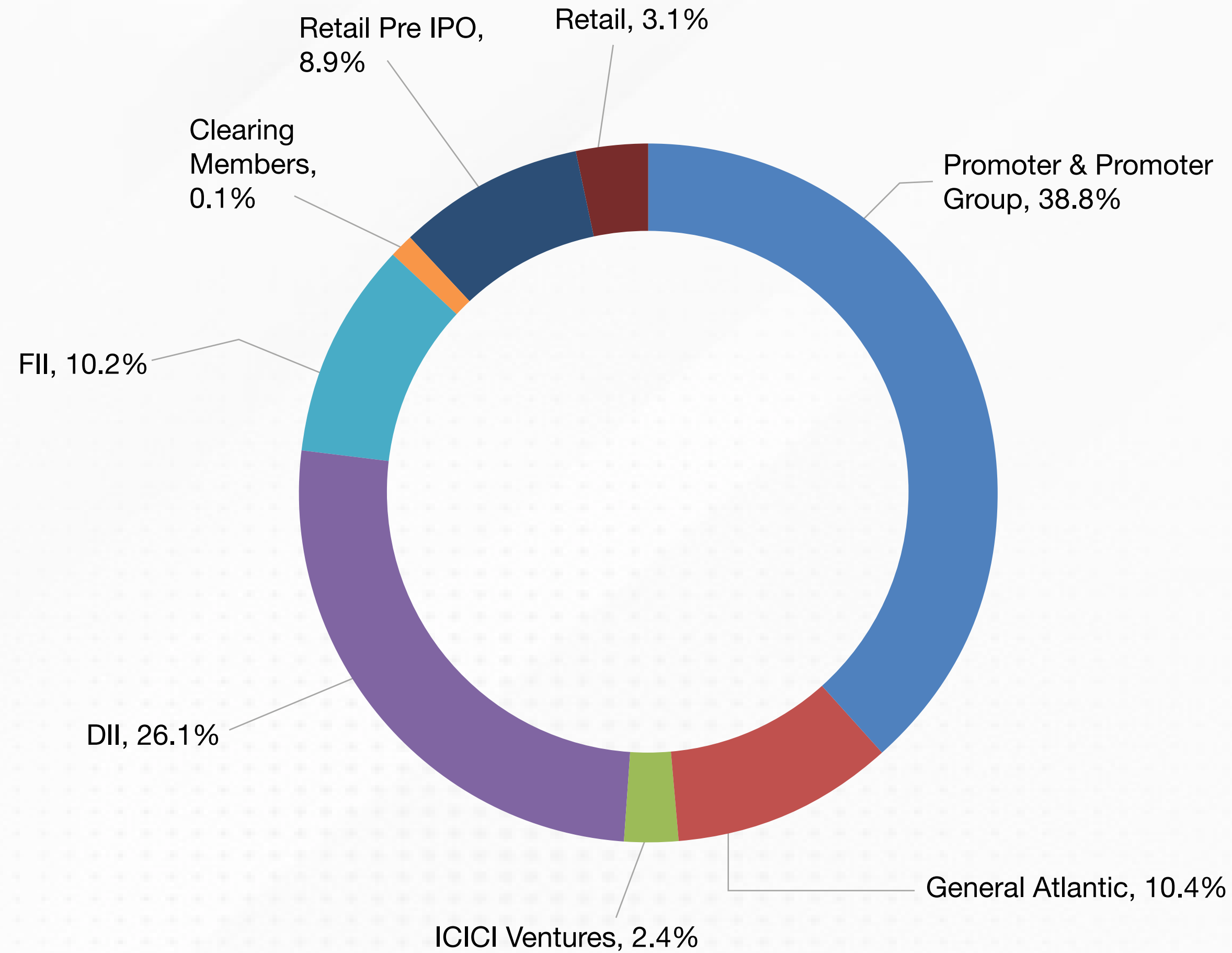


Mr. Ratna Kishore Kaza
Independent Director



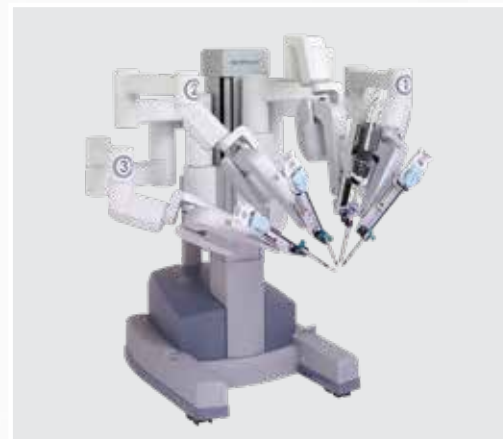Mrs. Y. Prameela Rani
Independent Director

Shareholding Pattern - 30th September, 2022



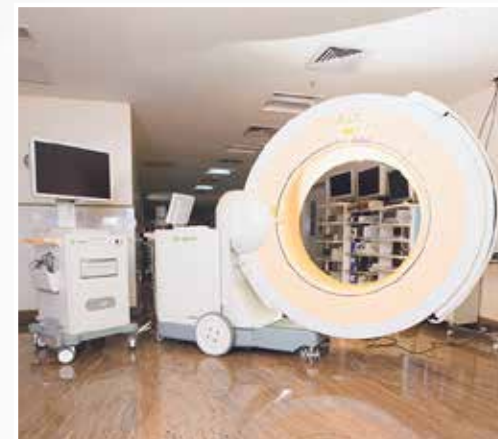| Share Holder | No of Shares | Share Holding % | Category |
|-----------------------------|--------------|-----------------|----------|
| Promoter | 31,086,304 | 38.84% | |
| General Atlantic | 8,339,147 | 10.42% | |
| ICICI Ventures | 1,939,393 | 2.42% | |
| Mirae Asset MF | 7,345,226 | 9.18% | DII |
| Axis MF | 5,017,687 | 6.27% | DII |
| ICICI MF | 2,058,695 | 2.57% | DII |
| ICICI Life Insurance | 1,721,472 | 2.15% | DII |
| Emerald Investments Limited | 1,570,000 | 1.96% | FII |
| Polar Capital Fund | 1,523,107 | 1.90% | FII |
| Nomura | 1,438,029 | 1.80% | DII |
| HDFC Life Insurance | 1,211,544 | 1.51% | DII |
| TATA AIA Life Insurance | 1,129,337 | 1.41% | DII |
| Vanguard Equity Funds | 982,885 | 1.23% | FII |

Modern Medical Technology



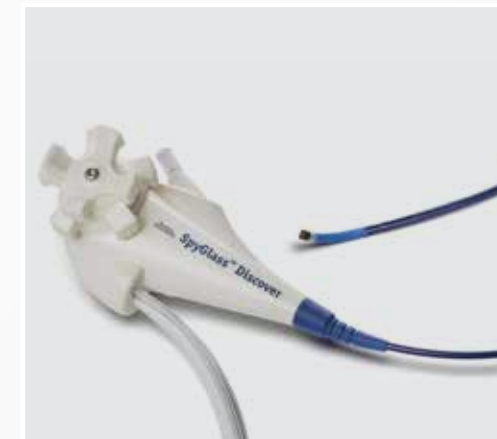4-Arm HD da Vinci Robotic Surgical System

Facilitates complex surgeries that are virtually scar less



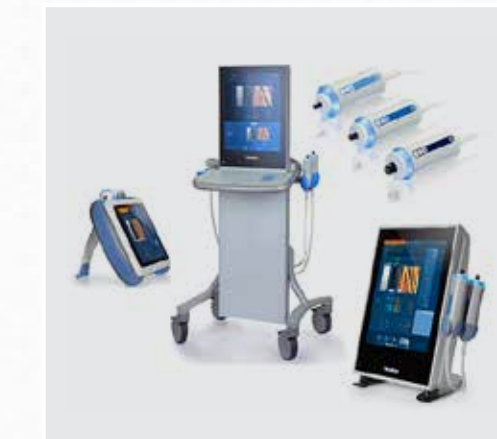O-Arm Scanner

Multi-dimensional surgical imaging platform optimized for use in spine, orthopaedic, and trauma-related surgeries



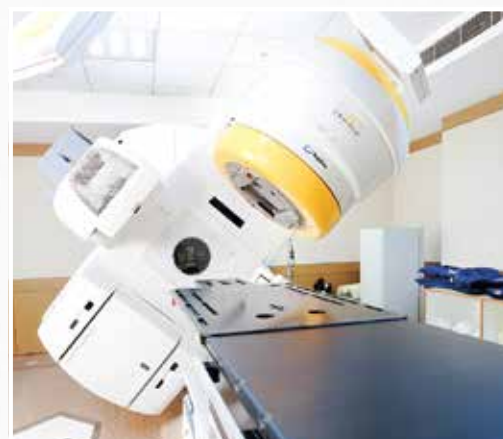Spy Glass

State of the art add on to ERCP that allows doctors to observe patients' biliary duct system and other tiny ducts in the pancreas



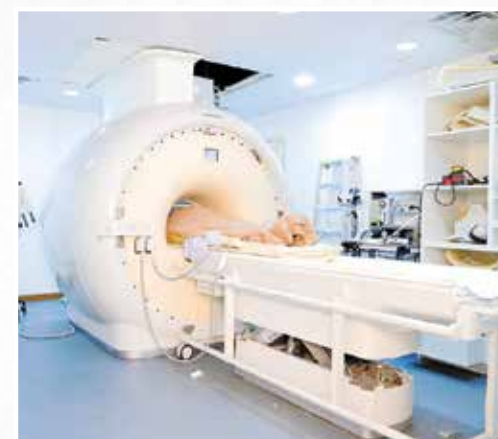Fibroscan

Specialized non-invasive diagnostic ultrasound-based device that measures fibrosis and steatosis caused by different liver diseases



Novalis Tx Linear Accelerator

Machine used in radiosurgery and radiotherapy for treating cancer patients



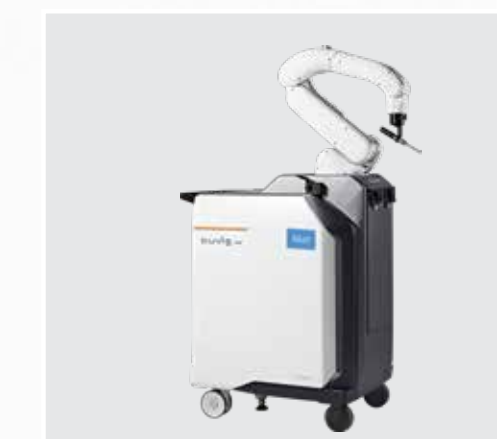3 Tesla MRI

Non-invasive diagnostic imaging technique performing faster scans and gives improved diagnostic sensitivity and specificity



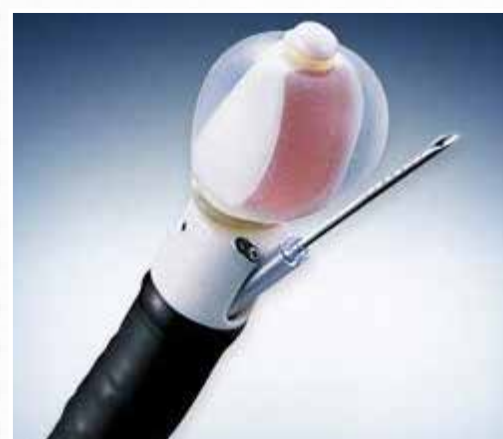Mako Robotic for Knee Replacement

Produces minimal blood loss and a smaller scar. Helps preserve healthy bone and soft tissue. Results in less post-operative pain than manual techniques.



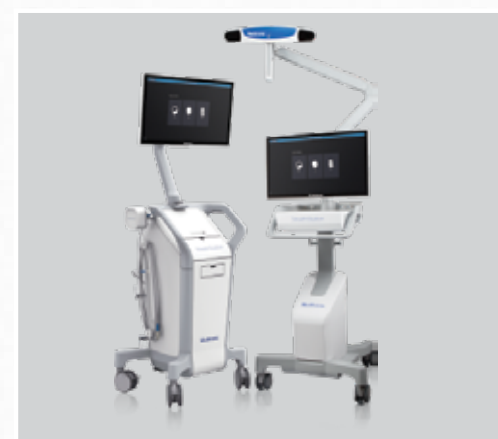Cuvis Ortho Robo

The most advanced surgical equipment capable of 3D pre-planning, virtual surgery and precise cutting to provide accurate and precise surgery results



EBUS

Used to diagnose lung cancer, infections, and other diseases causing enlarged lymph nodes in the chest



STEALTH STATION S8

Provides the Neuro surgeon to use data intraoperatively for advanced visualization.



IMPELLA

Impella, the world's smallest heart pump, is a percutaneous catheter-based technology that provides hemodynamic support to the heart



EVIS X1 Endoscopy System

The most advanced Endoscopy system helps improving clinical outcomes by providing Endoscopist with innovative and proven tools.

Many Firsts...

- **First in Asia** in to do Trans catheter Tricuspid Valve replacement procedure done in 2018
- **Largest** Joint replacement program in South Asia.
- **One of the largest** neuroscience programs for epilepsy among private hospitals in the country
- **Largest** ECMO program (18 machines) in the country.
- **First hospital in Hyderabad** to use an ECMO machine in 2013.
- **First hospital in Hyderabad** to do a Neonatal ECMO
- **First in India** to do TOF repair using CorMatrix patch for pulmonary valve reconstruction in 2017
- **First in the country** to do Robotic spleen preserving distal pancreatectomy

- **India's first** COVID Double Lung transplant done in 2020
- **India's first** Breathing Lung transplant done in 2021
- **First hospital in South India** to introduce Da Vinci Robotic System
- **The first hospital in Andhra Pradesh** and Telangana to have been Green OT certified in 2016
- **First hospital in India** to perform Arch Repair in Neonates and infants without TCA
- **First Hospital in South India** to do Total Skin Electron Beam Radiation therapy in 2018
- **Number 1 player** in Organ transplantation speciality (Heart, Lung, Liver and Kidney)*

- **Number 1** in Nephrology treatments in Andhra Pradesh*
- **Number 1** in Neurosurgery & Poly trauma treatments in Andhra Pradesh*
- **Number 1** in Cardio related surgeries and treatments programs in Andhra Pradesh *
- **Number 1** in Urology (Genito-Urinary) surgeries performed in Andhra Pradesh*

Key Accomplishments



Ranked No. 1 Hospital
by Times of India, Hyderabad



'Best Patient Friendly Hospital'
AHPI Health Care Excellence
Award (2017)



'Best Hospital to Work For'
AHPI Global Conclave
Award (2019)



Pharmacie De Qualite (PDQ)
Certification Overall PDQ Evaluation
Performance Score - 98%
Grading - PLATINUM



2nd Best Hospital in
Hyderabad (2021)



20th National Award for
Excellence in Energy Management
Award 2019



National Quality Excellence
Awards 2019 for Best Super
Specialty Hospital in Telangana



2016
Neurology Department at
KIMS Secunderabad
ranked 3rd in India
Neurology India General




2019
KIMS Sec. Best Super-Specialty
Hospital in Telangana
National Quality
Excellence Awards



2020
Only Hospital in Telangana
to get NABH Accreditation for
Emergency Department



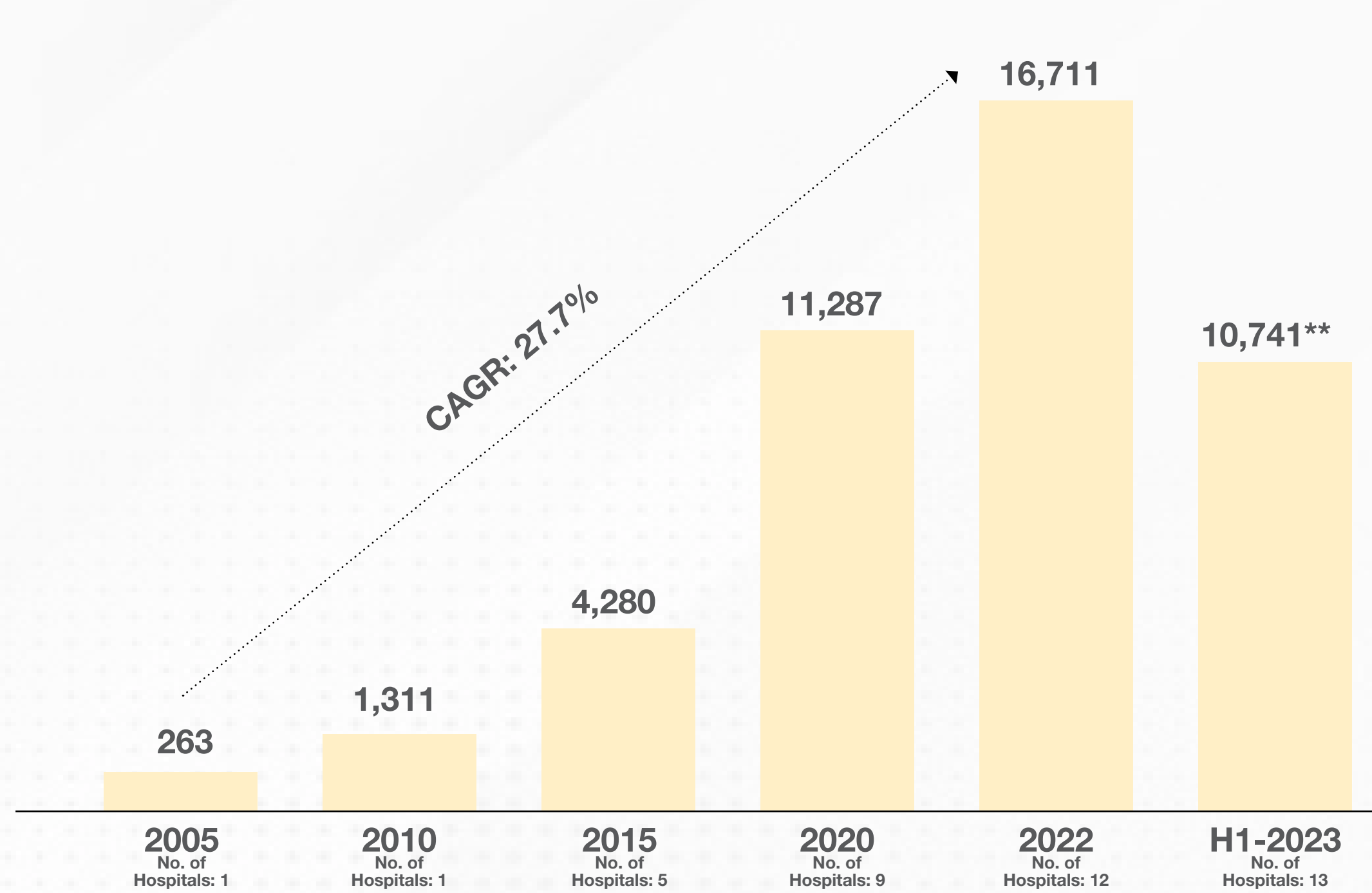
2021
Ranked No.1 in Hyderabad for
Cardiology, Neurosciences,
Nephrology & Emergency
Times Health Survey
Times of India



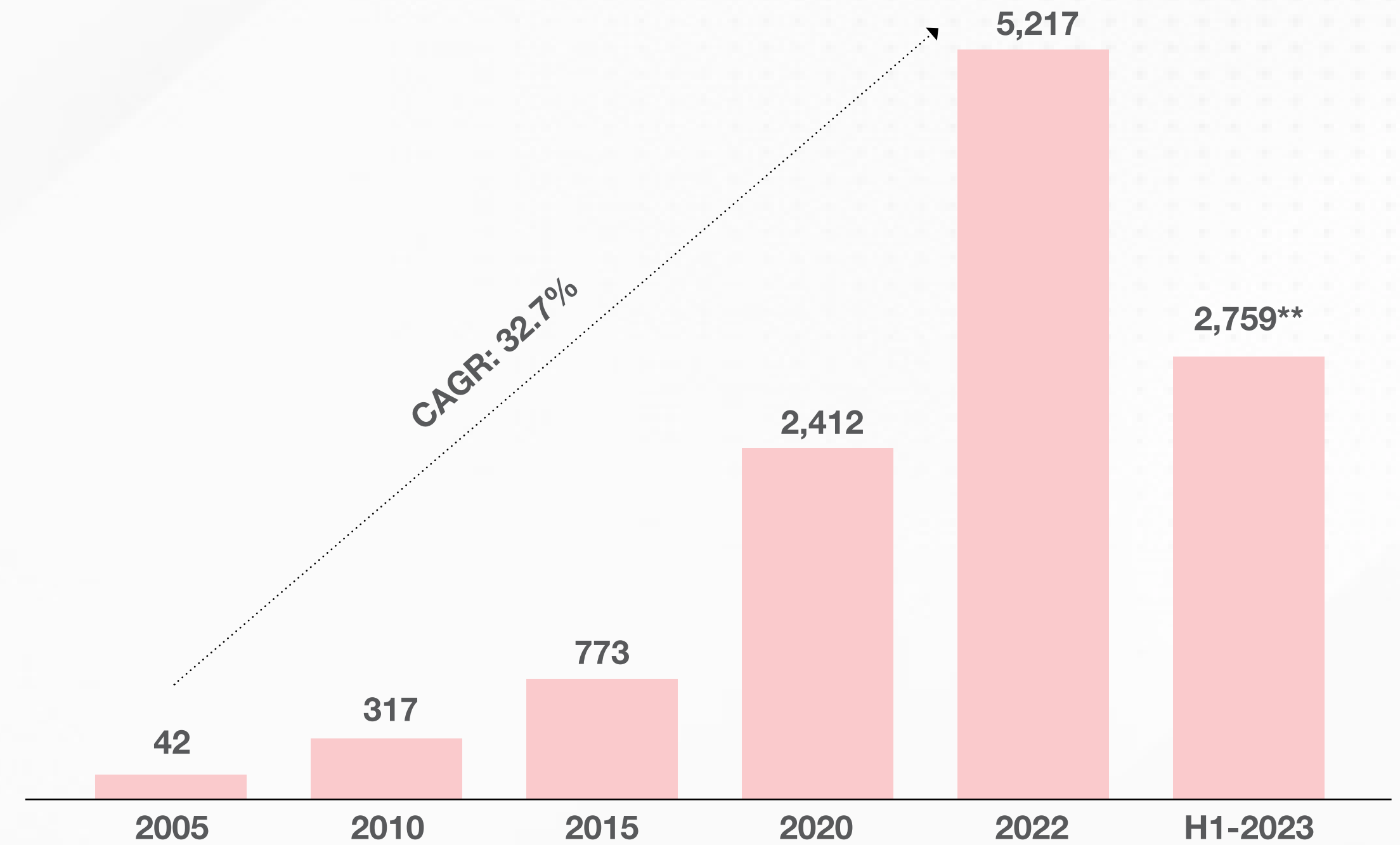


Consistent performer over 2 decades

(Rupees in Millions)



Total Revenue



***EBITDA**

*EBITDA before IND AS 116 and other income

**Revenue and EBITDA are including 1 month performance (Sep'22) of the new acquisition at Nagpur

Q2 Updates

Stellar performance across parameters

HIGHEST EVER
REVENUE*
FOR A QUARTER

INR **5,733** Mn

HIGHEST EVER
EBITDA**
FOR A QUARTER

INR **1,447** Mn

HIGHEST EVER
DISCHARGES
FOR A QUARTER

46,000+

HIGHEST EVER
OP FOOTFALL
FOR A QUARTER

375,000+

*Revenue represents total revenue

**EBITDA before IND AS 116 and other income

FINANCIAL HIGHLIGHTS

Q2 FY 23 Consolidated

- From 1st September'22, M/s SPANV Medisearch Lifesciences Private Limited (Kingsway Hospital, Nagpur) has become a subsidiary of "KIMS Hospitals", post-acquisition of a 51% stake. It will be first operating hospital of the group outside Telangana & Andhra Pradesh.
- From 1st July 2022 KIMS Manavata has become our subsidiary which is undertaking Nashik project
- Consolidated Key Financials figures are as follows (Rs in Mn) :

Key financials figures ex Nagpur Hospitals also provided for better QoQ comparison, since "Kingsway hospital, Nagpur" has become subsidiary wef 1st Sep'22.

| Particulars | Current Year | | Pr. Year | Change % | | Q2 FY23 Consolidated Ex Nagpur | | |
|--|--------------|----------|----------|----------|-------|--------------------------------|----------------------------|---------------------|
| | Q2 FY 23 | Q1 FY 23 | Q2 FY 22 | QoQ | YoY | Nagpur Sep'22 (1 Month) | Consol Ex. Nagpur Q2 FY 23 | QoQ var % Ex Nagpur |
| Total Income | 5,733 | 5,008 | 4,171 | | | 143 | 5,590 | |
| Less : Other Income | 92 | 53 | 54 | | | 1 | 91 | |
| Revenue from Operations | 5,641 | 4,955 | 4,117 | 13.8% | 37.0% | 142 | 5,499 | 11.0% |
| Reported EBITDA (Including other income) as per Financials | 1,616 | 1,425 | 1,342 | 13.4% | 20.5% | 15 | 1,602 | 12.4% |
| Less : Other Income | 92 | 53 | 54 | | | 1 | 91 | |
| Less : INDAS 116 | 77 | 59 | 9 | | | - | 77 | |
| EBITDA Pre INDAS & Other Income | 1,447 | 1,312 | 1,279 | 10.3% | 13.1% | 14 | 1,433 | 9.2% |
| EBITDA % to Revenue from Operations | 25.7% | 26.5% | 31.1% | | | 9.9% | 26.1% | |
| Add : One off Old Luxury Tax Settlement | 55 | | | | | | 55 | |
| Adjusted EBITDA | 1,502 | 1,312 | 1,279 | 14.5% | 17.4% | 14 | 1,488 | 13.4% |
| Adjusted EBITDA % | 26.6% | 26.5% | 31.1% | | | 9.9% | 27.1% | |

FINANCIAL HIGHLIGHTS

- Consolidated Revenue from operation grew by 13.8% QoQ basis to Rs. 5,641 mn, Ex Nagpur grew by 11%.
- Consolidated Adjusted EBITDA (Excluding Other Income, INDAS adjustments and old case of Luxury Tax payment) grew by 14.5% on QoQ basis to Rs. 1,502 mn, Ex Nagpur grew by 13.4% to Rs. 1488 mn.
- Consolidated Adjusted EBITDA Margin stands at 26.6%, Ex Nagpur stands at 27.1% (QoQ improvement of 0.6%).
- Consolidated PAT (excluding fair value gain) grew by 15.1% on QoQ basis to Rs. 912 mn
- The group continues to have a very strong balance sheet along with healthy operating cash flow and has built a strong financial foundation for the next phase of growth.

OPERATIONAL HIGHLIGHTS

Q2 FY 23 Consolidated

All Operational parameters (IP, OP volume, ARPP & ARPOB) have shown improvements at the group level on YoY basis.

- IP Volumes and OP Volumes grew by 17.5% & 15.5% respectively on QoQ basis and 28.8% & 33.8% on YoY basis
- ARPP has declined slightly by 3.1% to Rs 1,21,302 on QoQ basis and improved by 5.8% on YoY basis
- ARPOB has declined slightly by 3.0% to Rs 29,237 on QoQ basis and improved by 17.8% on YoY basis
- Bed Occupancy has improved from 65.5% to 72.6% on QoQ basis

DIGITAL INITIATIVES

During the quarter, steady progress was made on digital transformation with notable initiatives as below:

- Docs App 2.0 (An integrated app for doctors to manage patient progress) was rolled out across all units (except Nagpur and Sunshine).
- With the launch of Meta hOS EMPI, we have enabled KIMS Universal Healthcare ID (UHID) across all the sites (except Nagpur)
- Launched KIMS EHR (an inhouse developed Cloud-based Clinical Information System) which has further improved collaboration between care teams (Consultants, Nurses and Medical Ops.)

ESG INITIATIVES

KIMS, Secunderabad has partnered up with Smart Joules Pvt Ltd (SJPL) a prominent Energy Services Company (ESCO) in 2018. A new and innovative model known as JoulePAYS was executed wherein, KIMS makes Zero Capital investment to implement various Energy Conservation Measures (ECMs) across the hospital and gets a guaranteed energy savings of minimum 10% annually over the baseline energy consumption.

For the period Jul 2022 – Sep 2022:

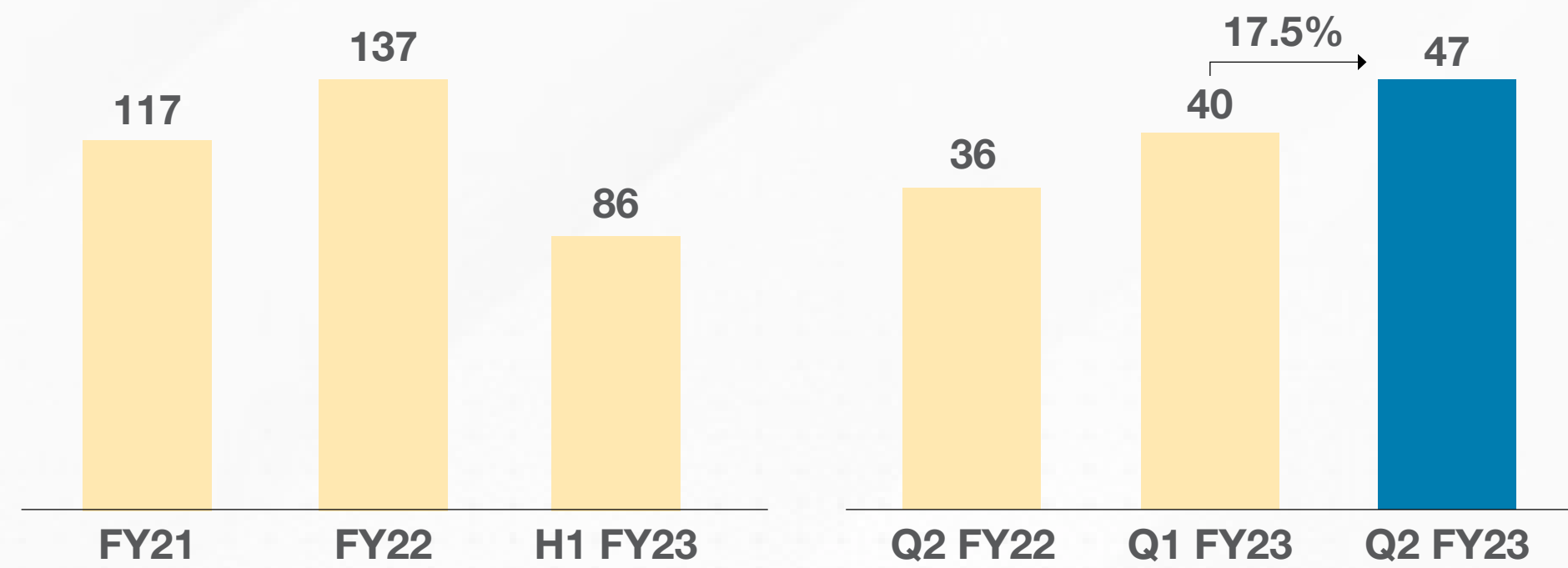
- 15.7 % of total energy consumption saved
- INR 55.16 lakhs of total energy cost saving achieved
- 319 tonnes of CO2 saved

In real life translation, the above translates to approximately the following:

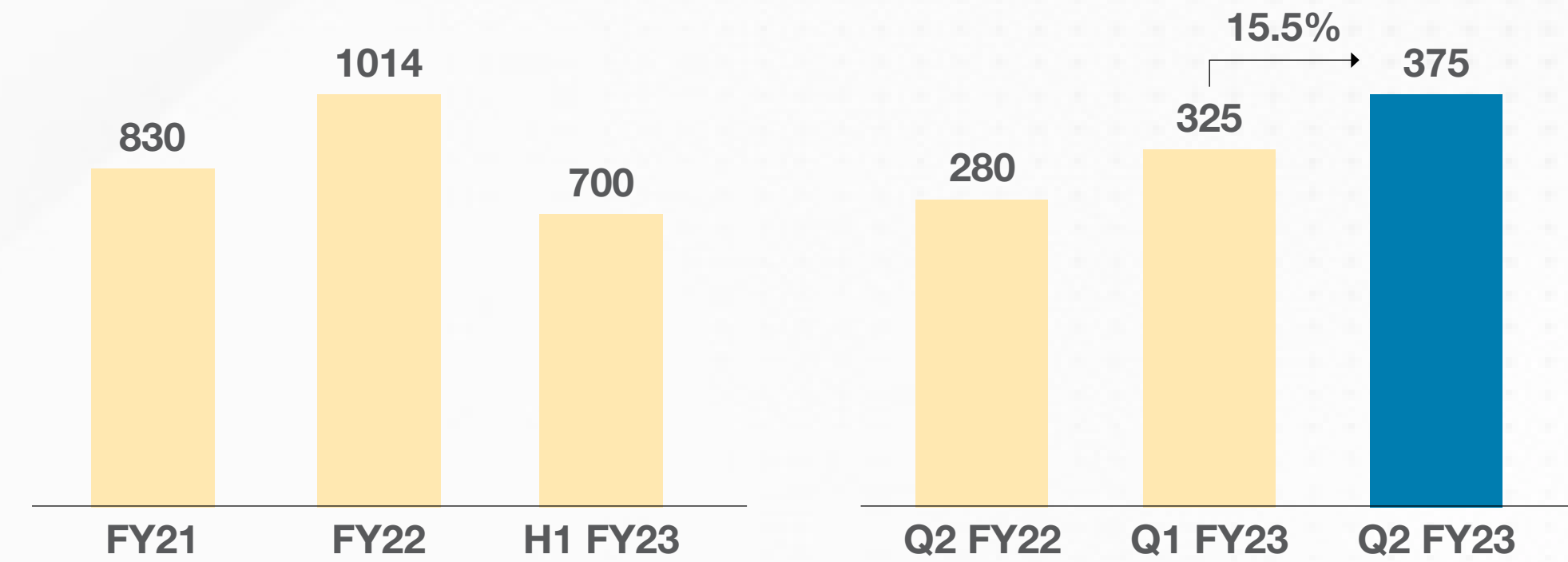
- 6,768 households getting electricity
- 12.89 Lakhs Kms less driven
- 13,067 trees planted

Group Operating Performance - 1/3

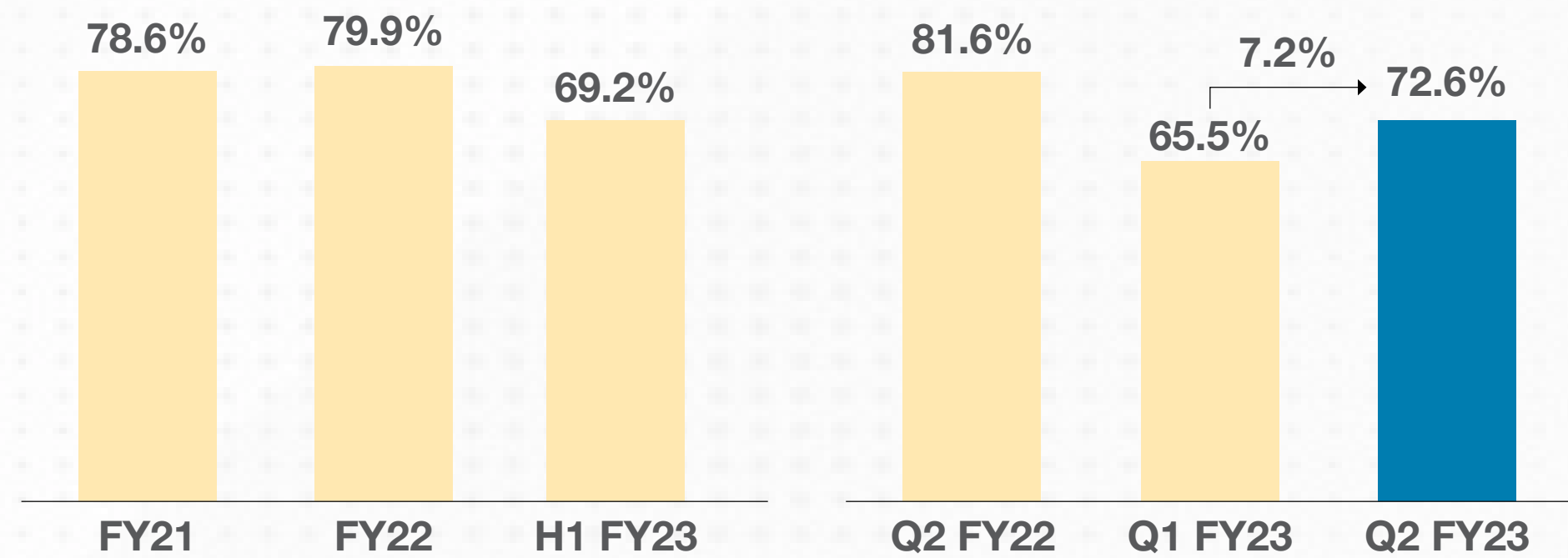
IP VOLUME ('000)



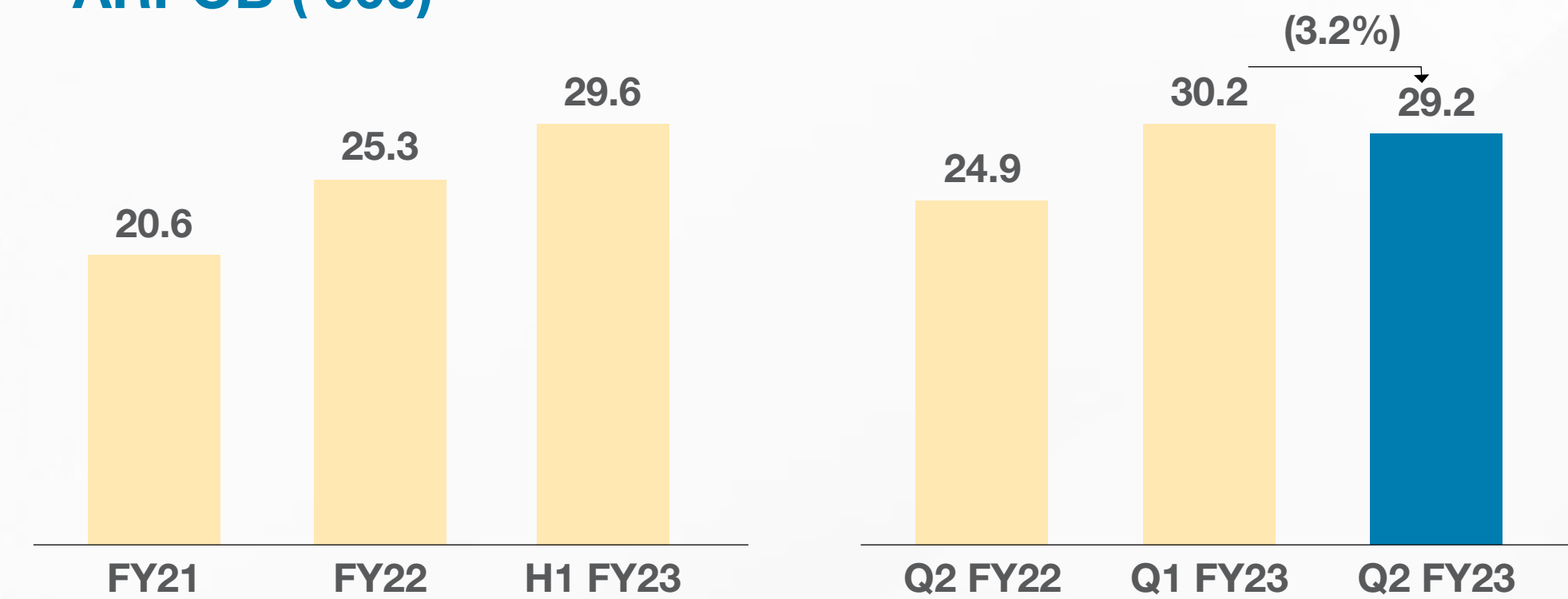
OP VOLUME ('000)



OCCUPANCY*



ARPOB ('000)

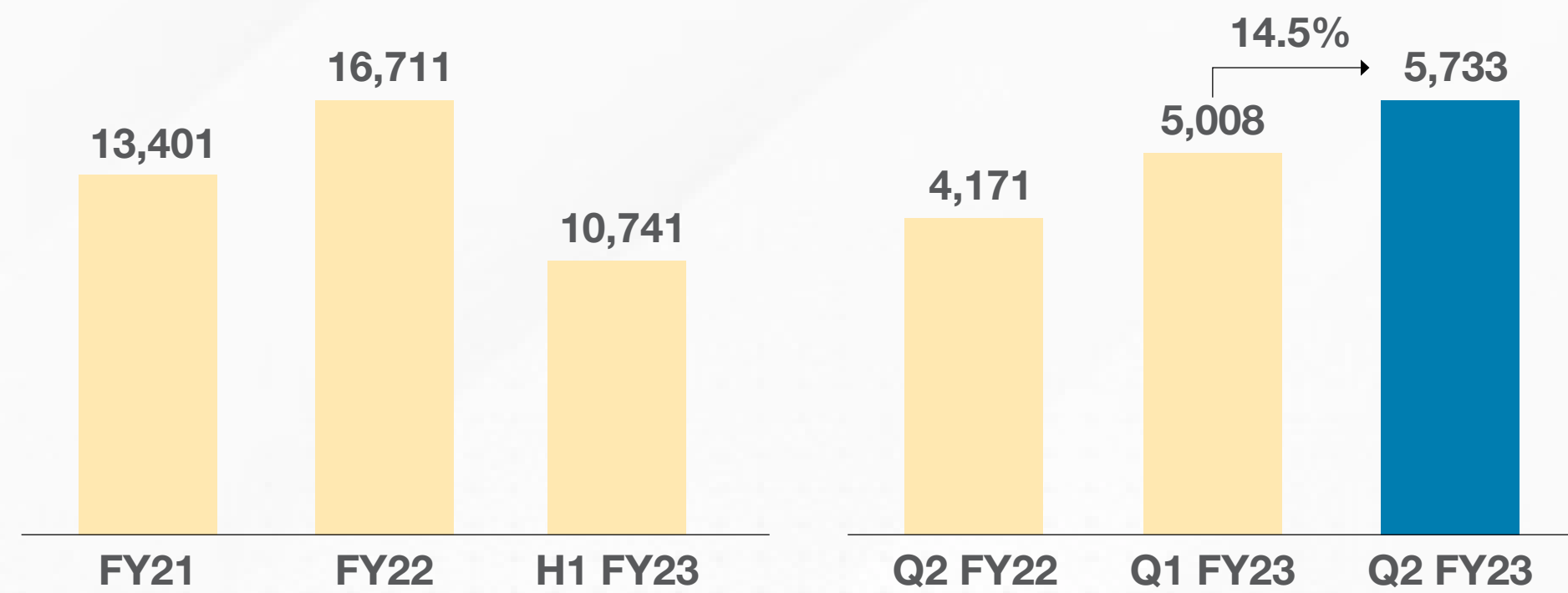


*Occupancy % based on operational Census Beds

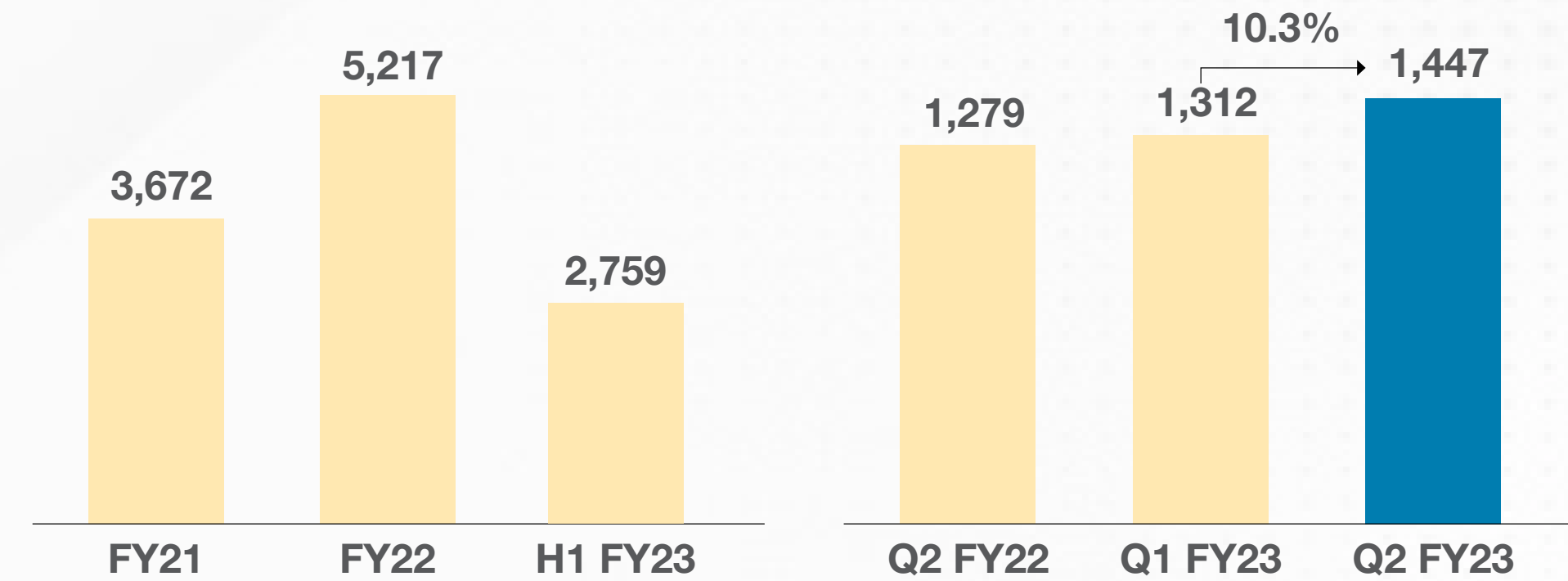
Group Operating Performance - 2/3

(Rupees in Millions)

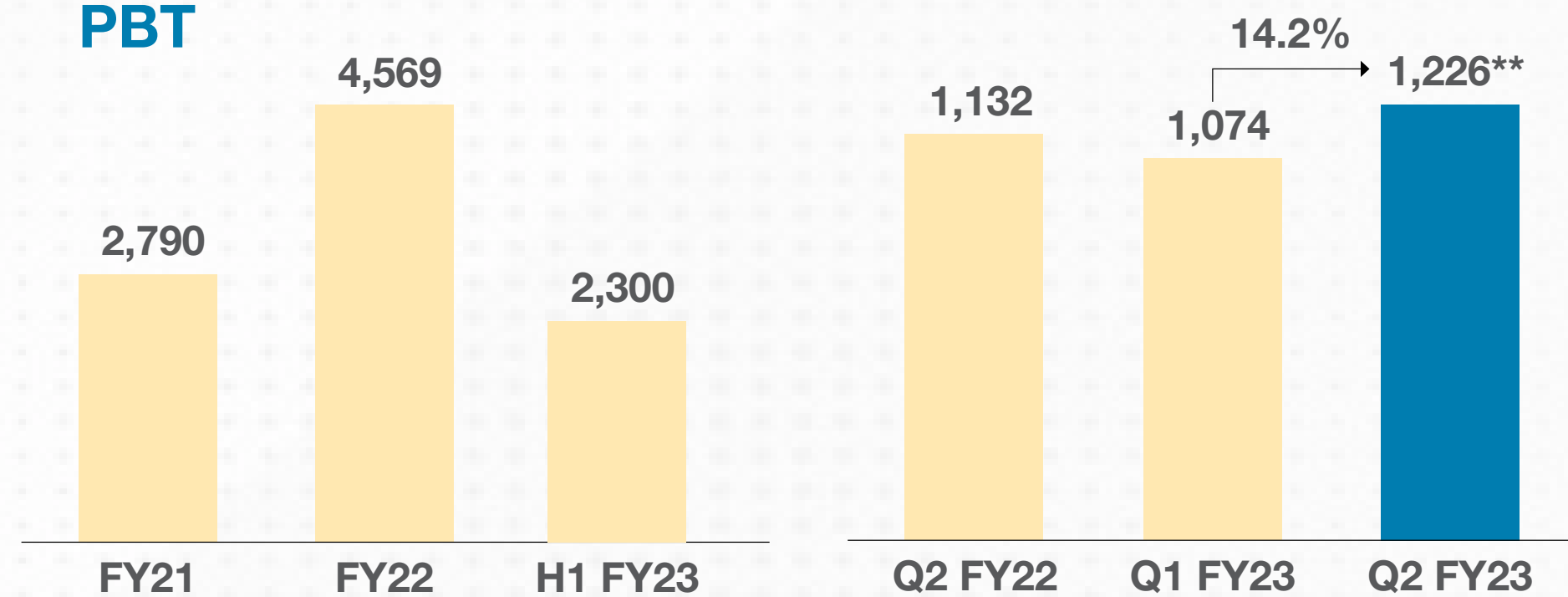
TOTAL REVENUE



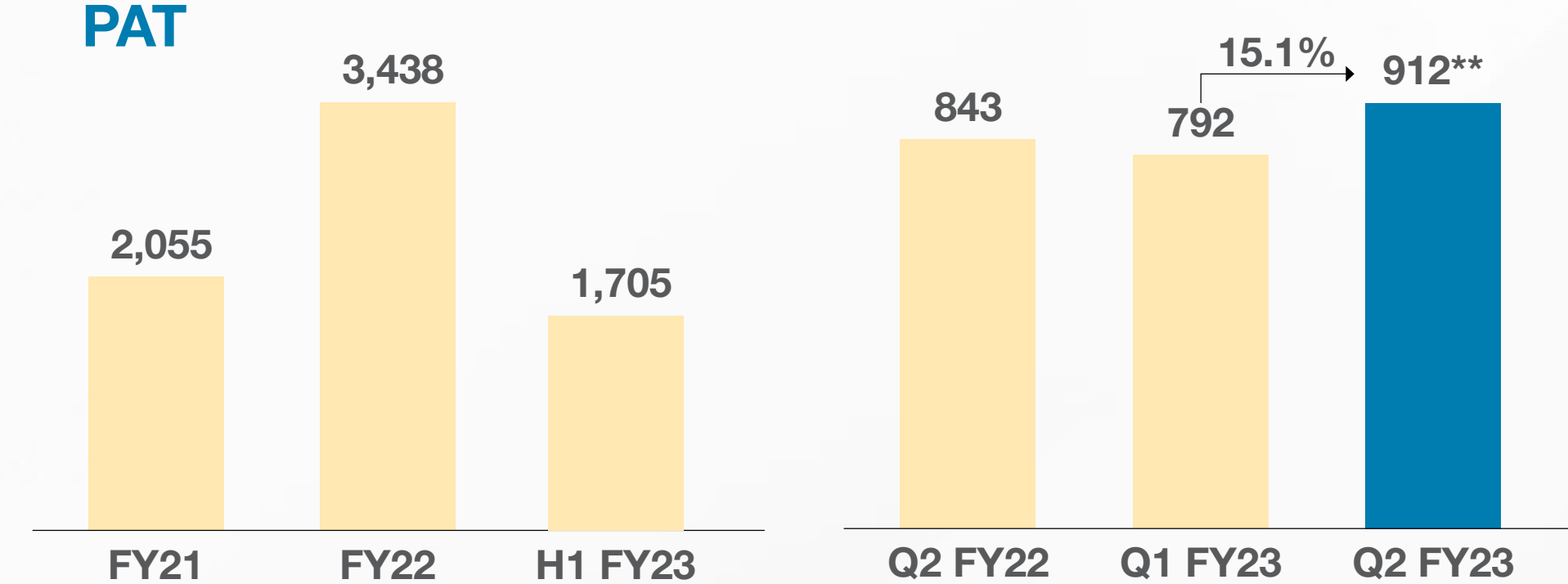
EBITDA*



PBT



PAT



*EBITDA before IND AS 116 and other income

**PBT and PAT are excluding fair value gain on acquisition of control amounting to INR 148.3 Mn

Group Operating Performance - 3/3

(Rupees in Millions)

| Particulars | FY21 | FY22 | Q1 FY23 | Q2 FY23 | H1 FY23 |
|------------------|---------|-----------|---------|---------|---------|
| Bed Capacity | 3,064 | 3,064 | 3,666 | 4,015 | 4,015 |
| Operational Beds | 2,590 | 2,590 | 3,222 | 3,543 | 3,543 |
| Census Beds | 2,246 | 2,246 | 2,760 | 3,026 | 3,026 |
| Non Census Beds | 344 | 344 | 462 | 517 | 517 |
| Occupied Beds | 1,765 | 1,793 | 1,807 | 2,223 | 2,108 |
| Occupancy | 78.6% | 79.8% | 65.5% | 72.6% | 69.2% |
| IP volume | 116,592 | 136,731 | 39,673 | 46,616 | 86,289 |
| OP volume | 830,211 | 1,013,759 | 324,797 | 375,188 | 699,985 |
| ARPOB | 20,609 | 25,323 | 30,192 | 29,237 | 29,640 |
| ARPP | 113,904 | 121,232 | 125,141 | 121,302 | 123,067 |
| ALOS | 5.53 | 4.79 | 4.14 | 4.15 | 4.15 |
| Total Revenue | 13,401 | 16,711 | 5,008 | 5,733 | 10,741 |
| EBITDA* | 3,672 | 5,217 | 1,312 | 1,447 | 2,759 |
| EBITDA % | 27.4% | 31.2% | 26.2% | 25.2% | 25.7% |
| PBT** | 2,790 | 4,569 | 1,074 | 1,226 | 2,300 |
| PAT** | 2,055 | 3,438 | 792 | 912 | 1,705 |

*EBITDA before IND AS 116 and other income

**PBT and PAT are excluding fair value gain on acquisition of control amounting to INR 148.3 Mn for Q2 FY23 and H1 FY23

Occupancy % based on operational Census Beds

Comparison of Telangana and Andhra Pradesh Matured Hospitals - 1/2

(Rupees in Millions)

| Particulars | Telangana (KIMS) | | | | | AP Matured Assets | | | | |
|------------------|------------------|---------|----------|---------|---------|-------------------|---------|---------|---------|---------|
| | FY21 | FY22 | Q1 FY 23 | Q2 FY23 | H1 FY23 | FY21 | FY22 | Q1 FY23 | Q2 FY23 | H1 FY23 |
| Bed Capacity | 1,200 | 1,200 | 1,200 | 1,200 | 1,200 | 630 | 630 | 630 | 645 | 645 |
| Operational Beds | 1,035 | 1,035 | 1,065 | 1,085 | 1,085 | 580 | 580 | 580 | 595 | 595 |
| Census Beds | 856 | 856 | 886 | 906 | 906 | 515 | 515 | 515 | 530 | 530 |
| Non Census Beds | 179 | 179 | 179 | 179 | 179 | 65 | 65 | 65 | 65 | 65 |
| Occupied Beds | 586 | 642 | 656 | 668 | 662 | 413 | 405 | 356 | 411 | 384 |
| Occupancy | 68.5% | 75.0% | 74.1% | 73.8% | 73.9% | 80.3% | 78.7% | 69.1% | 77.6% | 73.4% |
| IP volume | 45,087 | 53,567 | 14,001 | 15,959 | 29,960 | 30,503 | 30,963 | 7,548 | 8,361 | 15,909 |
| OP volume | 331,709 | 435,663 | 129,229 | 143,885 | 273,114 | 209,178 | 194,429 | 49,017 | 53,313 | 102,330 |
| ARPOB | 39,571 | 46,745 | 42,581 | 46,310 | 44,473 | 13,608 | 15,194 | 16,901 | 16,465 | 16,666 |
| ARPP | 187,738 | 204,519 | 181,687 | 178,435 | 179,955 | 67,303 | 72,566 | 72,491 | 74,487 | 73,540 |
| ALOS | 4.74 | 4.38 | 4.27 | 3.85 | 4.05 | 4.95 | 4.78 | 4.29 | 4.52 | 4.41 |
| Total Revenue | 8,560 | 11,066 | 2,562 | 2,904 | 5,466 | 2,060 | 2,252 | 549 | 624 | 1,173 |
| EBITDA* | 2,705 | 3,987 | 790 | 844 | 1,634 | 518 | 554 | 177 | 200 | 377 |
| EBITDA % | 32% | 36% | 31% | 29% | 30% | 25% | 25% | 32% | 32% | 32% |

*EBITDA before IND AS 116 and other income

Intercompany eliminations and dormant units are adjusted in Telangana

1) Telangana - Secunderabad and Kondapur

2) AP Matured Assets - Nellore, Rajahmundry and Srikakulam

Comparison of Andhra Pradesh Acquired, Sunshine & Nagpur - 2/2

(Rupees in Millions)

| Particulars | AP Acquired Assets | | | | | Sunshine | | | Nagpur | Group | | | | |
|------------------|--------------------|---------|---------|---------|---------|----------|---------|---------|---------|---------|-----------|---------|---------|---------|
| | FY21 | FY22 | Q1 FY23 | Q2 FY23 | H1 FY23 | Q1 FY23 | Q2 FY23 | H1 FY23 | Q1 FY23 | FY21 | FY22 | Q1 FY23 | Q2 FY23 | H1 FY23 |
| Bed Capacity | 1234 | 1234 | 1234 | 1234 | 1234 | 602 | 602 | 602 | 334 | 3,064 | 3,064 | 3,666 | 4,015 | 4,015 |
| Operational Beds | 975 | 975 | 975 | 1011 | 1011 | 602 | 602 | 602 | 250 | 2,590 | 2,590 | 3,222 | 3,543 | 3,543 |
| Census Beds | 875 | 875 | 875 | 911 | 911 | 484 | 484 | 484 | 195 | 2,246 | 2,246 | 2,760 | 3,026 | 3,026 |
| Non Census Beds | 100 | 100 | 100 | 100 | 100 | 118 | 118 | 118 | 55 | 344 | 344 | 462 | 517 | 517 |
| Occupied Beds | 766 | 746 | 603 | 758 | 681 | 191 | 206 | 201 | 179 | 1,765 | 1,793 | 1,807 | 2,223 | 2,108 |
| Occupancy | 87.5% | 85.3% | 69.0% | 83.2% | 76.3% | 39.5% | 42.6% | 41.1% | 92.0% | 78.6% | 79.8% | 65.5% | 72.6% | 69.2% |
| IP volume | 41,002 | 52,201 | 12,567 | 14,718 | 27,285 | 5,557 | 5,901 | 11,458 | 1,677 | 116,592 | 136,731 | 39,673 | 46,616 | 86,289 |
| OP volume | 289,324 | 383,667 | 96,889 | 113,856 | 210,745 | 49,662 | 54,845 | 104,507 | 9,289 | 830,211 | 1,013,759 | 324,797 | 375,188 | 699,985 |
| ARPOB | 9,881 | 12,388 | 14,240 | 12,848 | 13,461 | 62,706 | 60,419 | 60,800 | 26,489 | 20,609 | 25,323 | 30,192 | 29,237 | 29,640 |
| ARPP | 67,381 | 64,631 | 62,226 | 60,890 | 61,505 | 196,464 | 194,104 | 195,249 | 85,035 | 113,904 | 121,232 | 125,141 | 121,302 | 123,067 |
| ALOS | 6.82 | 5.22 | 4.37 | 4.74 | 4.57 | 3.13 | 3.21 | 3.21 | 3.21 | 5.53 | 4.79 | 4.14 | 4.15 | 4.15 |
| Total Revenue | 2,781 | 3,392 | 787 | 899 | 1,686 | 1,110 | 1,162 | 2,272 | 143 | 13,401 | 16,711 | 5,008 | 5,732 | 10,741 |
| EBITDA* | 450 | 676 | 151 | 177 | 328 | 194 | 212 | 406 | 14 | 3,672 | 5,218 | 1,312 | 1,447 | 2,759 |
| EBITDA % | 16% | 20% | 19% | 20% | 19% | 17% | 18% | 18% | 10% | 27% | 31% | 26% | 25% | 26% |

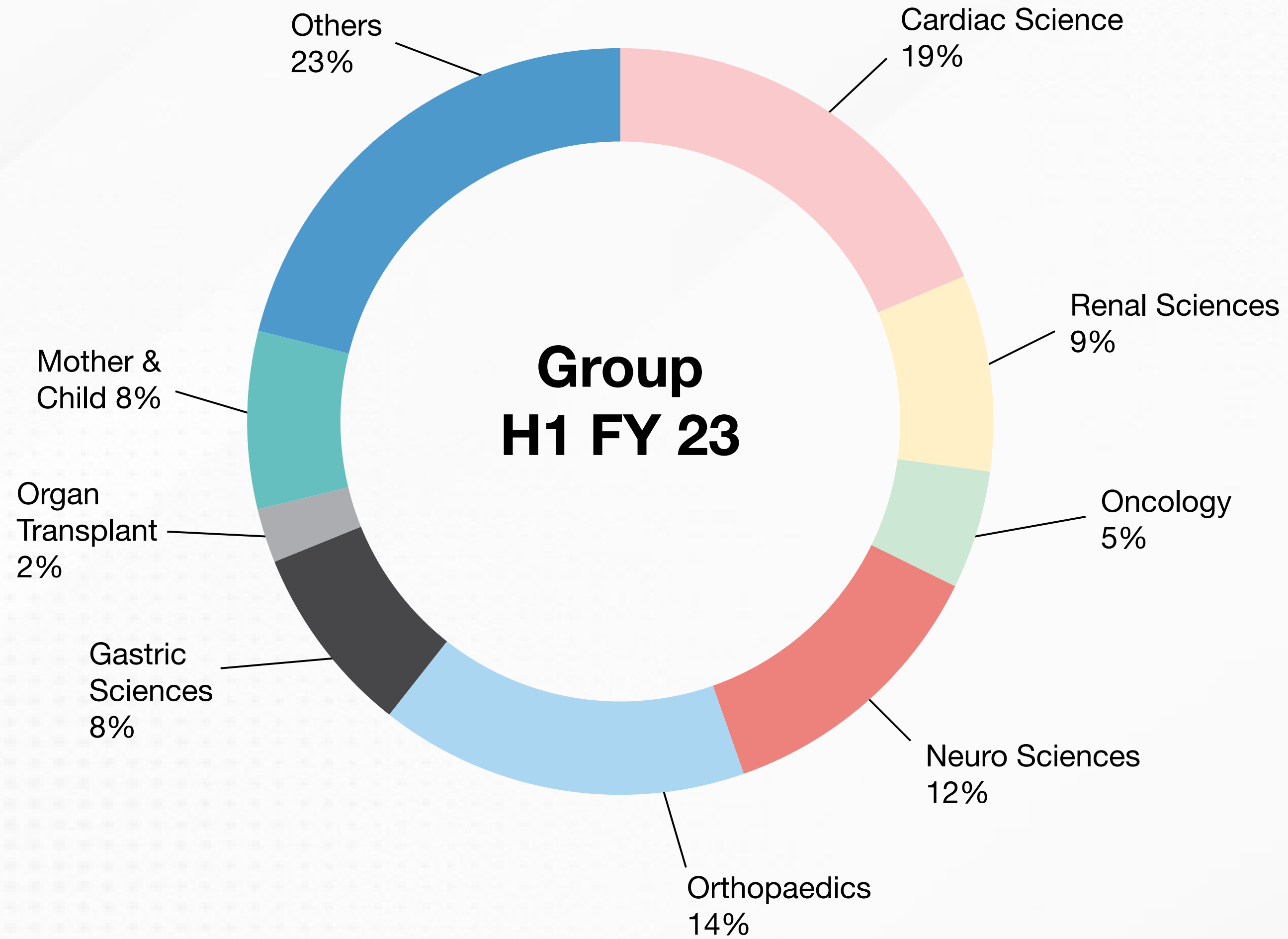
*EBITDA before IND AS 116 and other income

1) AP Acquired Assets - Ongole, Vizag, Anantapur and Kurnool

2) Sunshine - All 3 locations

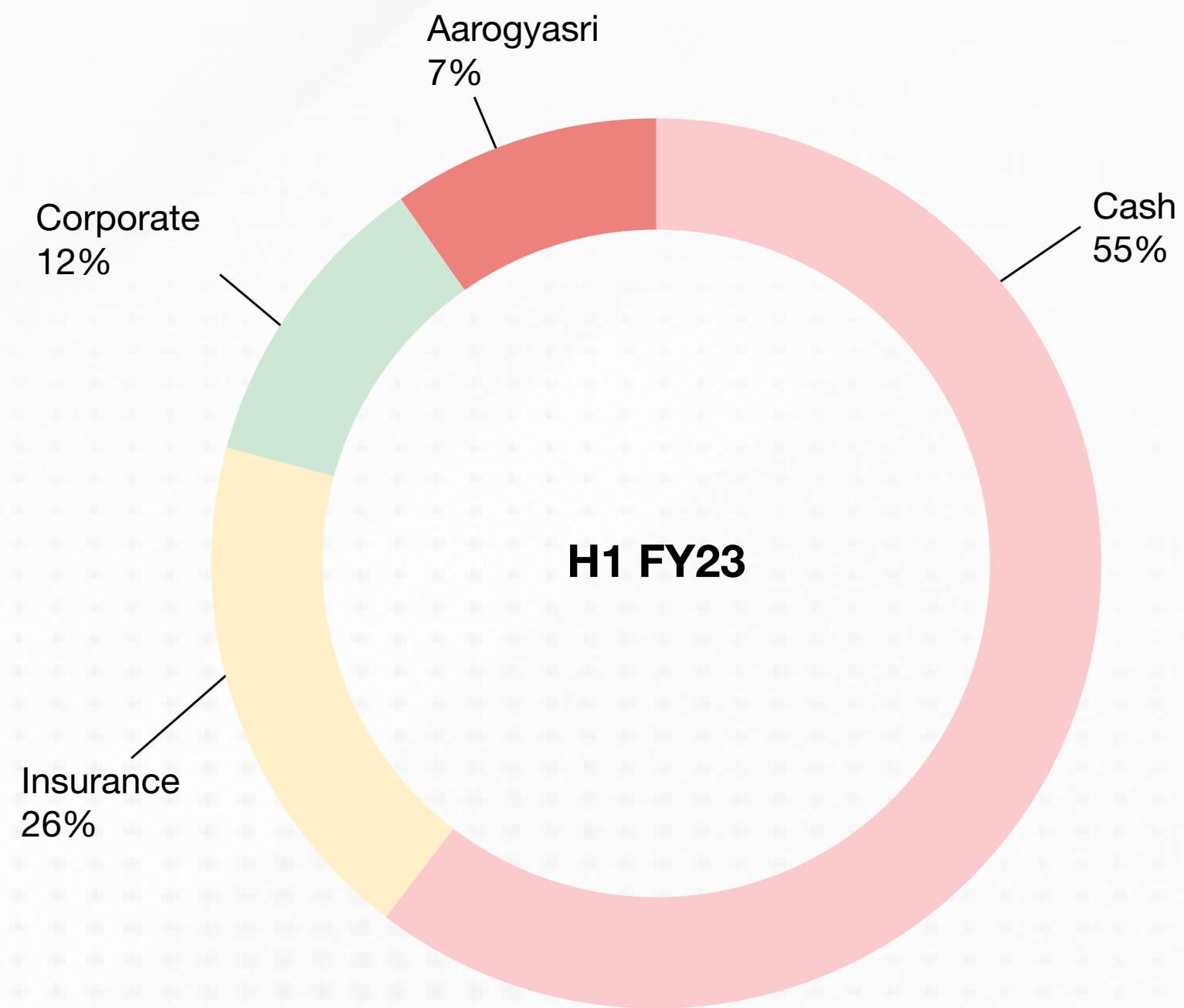
3) Nagpur - For the month of September 2022

Speciality Mix

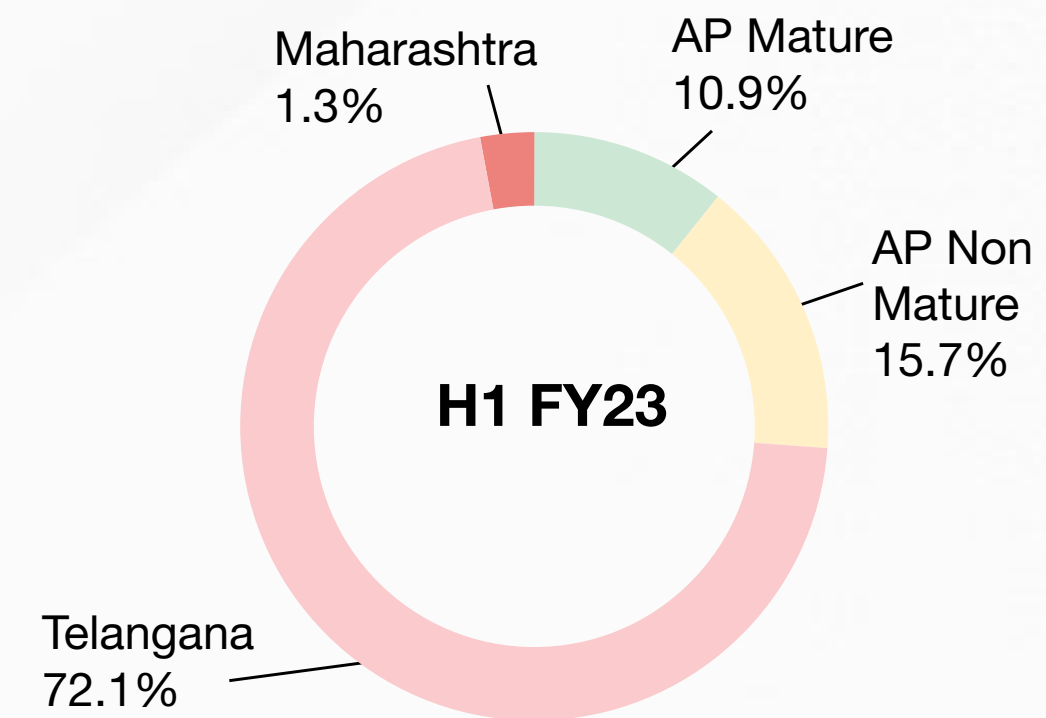


Includes Sunshine and 1 month (Sept'22) of Nagpur

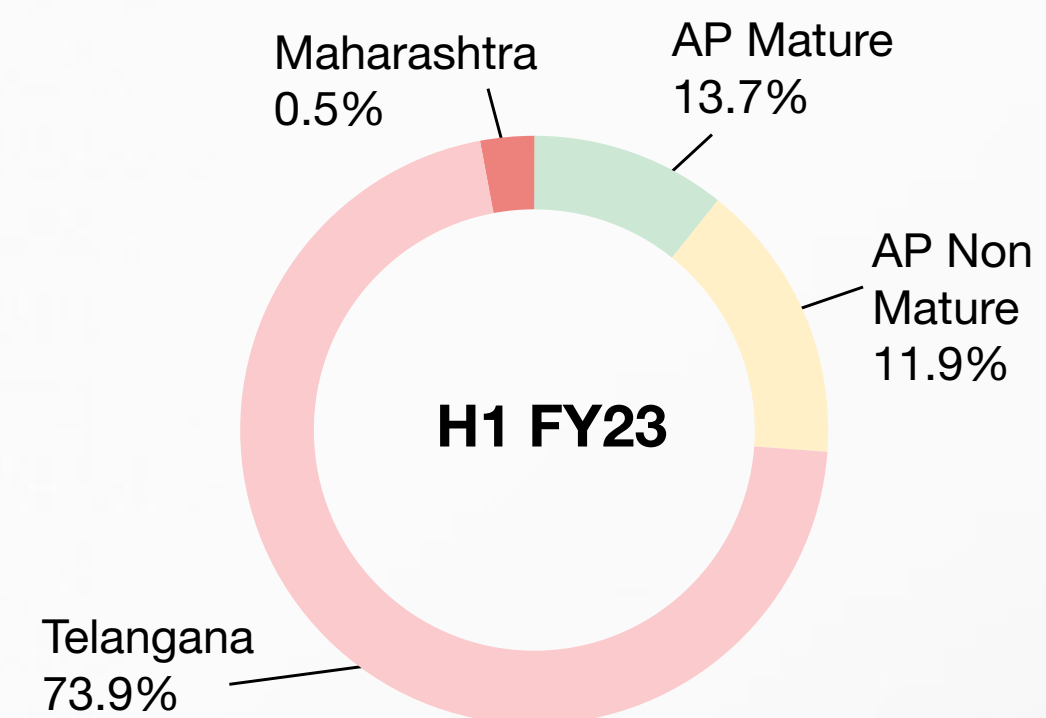
PAYOR MIX



CLUSTER TOTAL REVENUE



CLUSTER EBITDA*



*EBITDA before IND AS 116 and other income
 1) Telangana - Secunderad , Kondapur & Sushine 3 hospitals
 2) AP Mature - Nellore, Rajahmundry and Srikakulam
 3) AP Non Mature - Ongole, Vizag, Anantapur and Kurnool
 4) Maharashtra - Nagpur (1 month)

Key Achievements in Q2 FY23

KIMS Saveera doctors perform multiple surgeries on injured

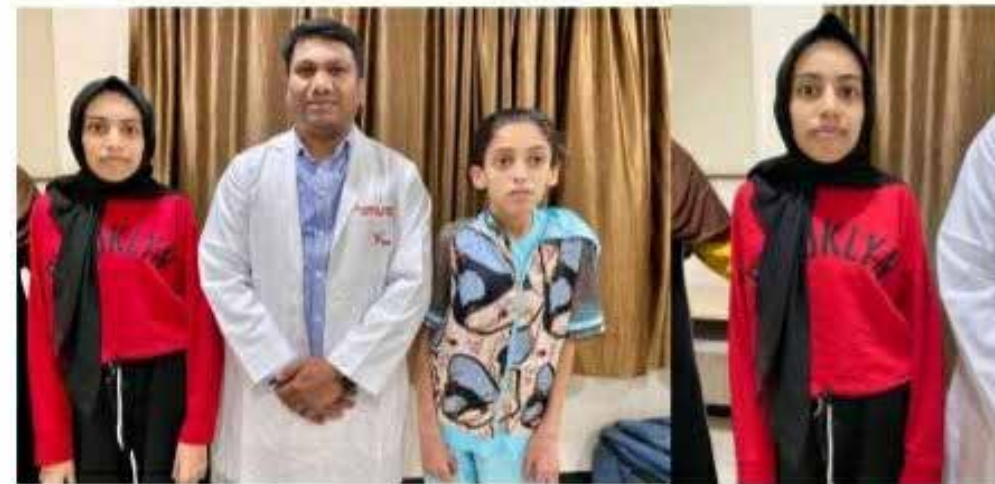ANANTAPUR

DOCTORS at KIMS Saveera Hospital in Anantapur performed six surgeries on a person, who fell from a huge tree and sustained severe fractures all over his body. Kumar, a 26-year-old man from Dibbasani-palle of Anantapur district, was seriously injured after he accidentally fell from a tall tree. He was in a critical condition as his ribs also were broken and his lungs were also damaged. Everyone thought it was almost impossible for him to survive. However, Dr Ramanjaneyulu, an orthopaedic surgeon at KIMS Saveera Hospital, examined his condition and his team decided to perform the surgeries one after another. He had to undergo a total of six surgeries.

They were performed one after another for a total of 14 hours. It took 10 days for him to recover from the surgeries. He got discharged from the hospital after a full recovery. Now he can do all his work. However, it takes about a month or two for all the broken bones to stick completely. He will have to visit the doctors once a month for three months. In the past, such complex cases were referred to the metro cities like Bengaluru or Hyderabad. With the availability of state-of-the-art medical facilities, an expert medical team and an anaesthesia team, he could survive at KIMS Saveera Hospital, examined his condition and his team decided to perform the surgeries one after another. He had to undergo a total of six surgeries.



Rare surgeries for Iraqi girls in KIMS Successful Surgical Treatment in a Complex Case



(By Our Skyline Staff Reporter) Hyderabad, July 7: Doctors at KIMS Hospital in Secunderabad have helped a mother who had crossed continents and came with a lot of hopes for the future of her two

Baghdad for treatment. They have been evaluated with spine X-rays. They came to know that both of them have a complex type of congenital Spinal deformity with multiple fused vertebral bones and ribs they are very small. Therefore, the doctors there said that the surgical outcome may be very poor. Finally, the parents took their two daughters to KIMS Hospital, Hyderabad. They presented to us at a stage

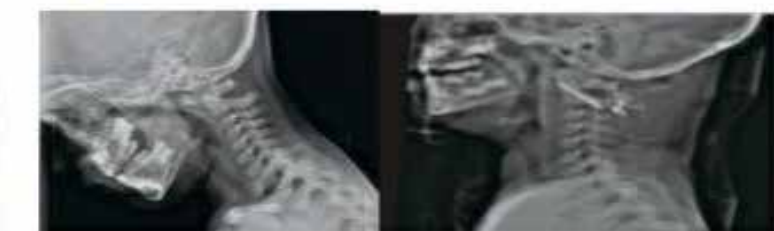pulmonologists, neuro-physiologists, nutritionists and physiotherapy experts. After considering the age of the children which is nearing the skeletal maturity age and also considering the poor socio-economic status of the parents, we wanted to cut down the cost of surgery. So, we have planned meticulously and decided to perform the surgery in a single phase. First, we passed the screws into the deformed spinal bones. We have installed a supporting rod on one side through screws. Later, we performed an osteotomy (removal of part of the bone, a method to correct the deformed bone) at the curvature (apex) where the spine is more inclined. In Hyderabad, and the state-of-the-art medical facilities like O-arm, neuro monitoring, spinal navigation, etc. Both the children underwent x-rays, whole-spine CT scans and MRI tests, and it was found that both of

erative neuromonitoring, we were able to correct the spine curvature as much as possible without putting pressure on the spinal cord and without causing any problems. After correcting the deformity we have checked for signals from the spinal cord with the help of intraoperative neuro monitoring and they are normal. The surgery was performed with the support of a team led by an anaesthesiologist Dr. Naresh Kumar. On the very first day of the surgery, we made both the children walk. A special spinal rehabilitation team at KIMS Hospital worked in this regard. On the fifth day of the operation, both the children were discharged in good

KIMS doctors saved the life of a child whose were damaged and couldn't hold the neck,

DECCAN NEWS SERVICE HYDERABAD

KIMS doctors saved the life of a three-year-old girl with a complicated surgery. Starting with the normal cold, the infection has spread and damaged the neck bones, putting her life in danger. Consultant Orthopaedics and Spine surgeon of KIMS Kondapur Dr K Sri Krishna CHAITANYA, Dr Ajay Kumar paruchuri and Paediatrician of KIMS Cuddles Dr Parag Dekate disclosed the details of the girl's problem and treatment given. "Atlanto-axial instability (a condition in which the neck bones are damaged and the neck is unable to stand. Due to this, even if the neck is slightly moved, the problem of breathlessness can lead to a life-threatening condition) which is very difficult to cure in three-year-olds. Their bones are very thin, with a circum-



signed to fuse the bones of children under the age of three. The three-year-old girl was recently brought to KIMS Kondapur hospital by her parents as she could not keep her neck fixed properly. We found that she had a pyogenic infection at C1 and C2 (Atlanta axial) in her neck bones. In three months, there has been some improvement, but the neck pain has not completely subsided. On further examination, we found that the bones near her neck were completely damaged and the stability of C1 and C2 was completely lost. However, her condition

along with neck pain. In the end, we decided to perform surgery using small screws called Herbert screws to fix her bone. A CT scan revealed that the girl's C2 isthmus was 2.6 millimetres in diameter (between the neck and the spine) and 20 to 24 millimetres in length. So we decided to use the screws and fix the small bones. However, by then the infection had spread and the bones had been severely damaged, and there were not enough bones to attach to the joint. So we thought of removing the bone from her mother's pelvis and

the pelvis of the mother and implanted intraoperative neural monitoring on the girl and started the surgery. Using a 2.4 mm Herbert screw system, we installed the screw with the help of guide wires and successfully corrected both the C1 and C2 joints. Atlas cables were also used from the back side to stabilize the attached bone. Artificial DMB and B-TPC have also been used to further increase the fusion. The girl was discharged from the hospital after six days as everything was fine with the X-rays taken after the surgery. This is the first time that people with similar problems have been successfully treated and documented in India, and there are very few in the world. With the use of accurate planning and technology, we have been able to provide a normal life to the child who is in a life-threatening situation again," said Dr K. SriKr-

KIMS doctors remove 2-cm stone from 9-month-old baby boy's kidney

KURNOOL

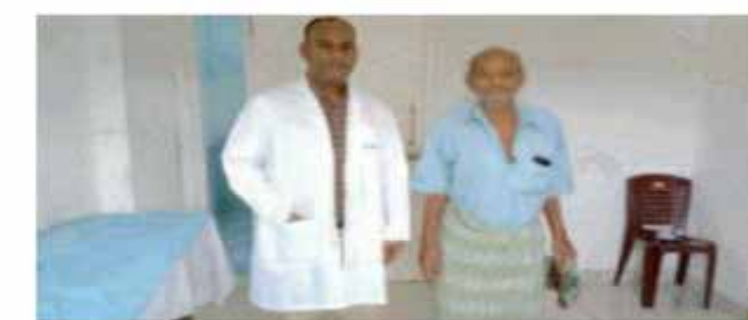THE doctors in KIMS Hospital successfully removed a 2-cm stone from a kidney of 9-month-old baby boy on Saturday. When the parents took him to a local doctor, he performed an ultrasound scan and informed them about the stone. As the stone was large and the boy was only 9 months old, he was referred to urologist Dr Manoj Kumar at KIMS hospital. Considering the young age of the baby boy, Dr



Manoj Kumar removed the large stone using endoscopic method with a very small incision. This is the first time in Kurnool town that

such a large stone is being removed in an endoscopic manner from a 9-month old baby. "Technically, it is a very challenging surgery for children of such a young age. However, we have successfully operated it. Complete metabolic evolution, urine analysis has to be done and medicines need to be used to control any unusual conditions if any," Dr Manoj Kumar explained.

KIMS Icon doctors gave a new life to a 70 year old man who was not even able to walk



DECCAN NEWS SERVICE VISHAKHAPATNAM

A 70-year-old man, who had a long history of smoking, having undergone bypass surgery to his heart once before, and suffering from asthma, severe diabetes, and hypertension, was relieved by doctors at KIMS Icon Hospital in Visakhapatnam from a condition where he could not move his leg with another problem.

He got gangrene in his left great toe. For a long time, the flow of blood to the leg has been very reduced. Even while sitting, he is suffering from severe pain and not being able to take even four steps. The elderly man hails from the Gajuwaka area of Visakhapatnam. He consulted Dr. S.S. Amarendra Babu, a vascular and endovascular surgeon at KIMS Icon Hospital in this regard. He un-

derwent a thorough medical check-up. It turned out that both the legs were not getting pulses at all. It was observed that the aorta split into two and the left iliac artery, which supplies blood to the left leg, is completely clogged by 10 cm. Generally, for such problems, blood circulation should be restored from the aorta to the left leg through a bypass operation by cutting the abdomen open. But the patient was already suffering from diabetes and blood pressure. It has been decided to undergo surgery in the endovascular method as it will take longer to recover as he is also a heart patient. It is very rare to do such procedures in the Visakhapatnam area. Due to this, only a small hole was made without cutting the stomach and leg and without

stitches and a stent of ten centimeters was inserted. Through this, the entire flow of blood to the leg was restored. As a result, the patient's leg problem was completely cured and he was able to walk on his own. Due to gangrene, he had to remove his finger and was discharged from the hospital till the injury healed. In normal surgery, anesthesia should be given, which would have caused more problems as he was already a patient with asthma. In addition, there were some problems in terms of his age even if it was major surgery Dr. S.S. Amarendra Babu Vascular and Endovascular Surgeon at KIMS Icon Hospital, said the surgery was performed in an endovascular manner to prevent them and the patient has made a full recovery.

Key Achievements in Q2 FY23

All the organs in the stomach are disorganized in a road accident



Gastroenterologist explained the case details. "Other than COVID, there will be several reasons for low saturation. We performed emergency laparoscopic surgery. We found that due to the severe accident, he had an injury to the diaphragm (A wall between the lungs and stomach). There was a 7 cm rent in the diaphragm with the stomach colon and omentum slipped from the abdomen into the chest cavity. As traumatic liver was very close to the injured diaphragm. Because of all these complex conditions, the surgery was quite challenging. We have performed technically difficult surgery in emergency laparoscopically. All the contents were brought back to the abdomen and then the defect in the diaphragm was closed. A Surgery was laparoscopic, a big scar on the stomach was avoided and recovery was very fast. The patient was comfortable on the next day of surgery and off the ventilator too. He was ready for discharge on 4th day after surgery.

(Standard Post, Bureau) Hyderabad, July 20 : A 26-year-old youth was severely injured in a head-on collision accident between two bikes. Immediately after the injury, he was treated by a nursing home in the Nalgonda district on an outpatient basis. He was diagnosed with a case of injury over the chest with multiple abrasions over the body. He was treated symptomatically. After 24 hours of injury, he developed severe chest pain with difficulty in breathing. So, the local doctor referred the patient to a higher centre because of the high risk of surgery and the critical condition of the patient. The patient was then shifted to KIMS hospital in Secunderabad. He was administered 10Litre oxygen on high nasal flow oxygen, but still, the saturation was only 85%. Something other than COVID can also cause low oxygen saturation. His heart rate was around 140. After a thorough examination, assessment of chest x-ray and chest CT scan, diagnosis of traumatic injury of the diaphragm with herniation of stomach colon and omentum along with major liver injury was detected. Dr Sachin Daga, consultant Surgical

First ever cadaveric kidney transplant in Kurnool

Done at KIMS hospital under the Jeevandan program
A woman in Gadwal declared brain dead,
Proddutur woman gets a kidney



(By Our Skyline Staff Reporter) Kurnool, August.17: July 2022, she was called for a transplant. Mrs Charita, a 30- year-old with the Jeevandan for organ allocation, and then doing an HLA cross-ess rate many dialysis patients in the Rayalaseema region are

their kidneys- parents, siblings, spouse, and grandparents. If the patient's relatives are unfit for donation due to various reasons- medically unfit, blood group or HLA incompatibility. Such patients are registered in the cadaveric transplant program – Jeevandan in Andhra Pradesh. If anyone is declared brain dead as a result of intracranial bleeding, a road traffic accident or severe illness, or as a result of cardiopulmonary resuscitation

Woman who does not have an oesophagus at birth undergoes complex surgery



(Standard Post, Bureau) Kurnool, July 22 : We generally need the oesophagus to eat or drink she is going well with liquids, she is unable to even take ordinary solids like idly. Her parents, who space constraint to get it fixed there. Normally, the oesophagus is straight. But here, after growing, it got

everything was quit normal, without an leakages. We have teste up to about 50 cm in th small intestine and looke there too. It is also in normal state. As precautionary measure, pipe was also placed nee the oesophagus. In case c any problem with th corrected oesophagu again, it is possible t provide food through th pipe. The patient was ther in ICU for three days afte the surgery and anothe four days in the room Initially, she was give normal water, an x-ray wa taken to check whethe there was any leakage. A

ఐదు నెలల బాబుకు మెదడు శస్త్ర చికిత్స విజయవంతంగా చేసిన అనంతపురం కిమ్స్ వైద్యుల మొదటి శస్త్రచికిత్స



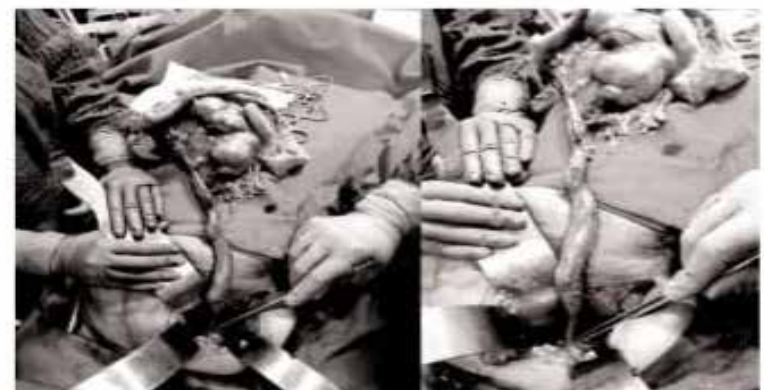అనంతపురం, జూలై 12 (అనంత న్యూస్) : అనంతపురం కిమ్స్ వైద్యులు మొట్టమొదటిసారి ఐదు నెలల బాబు మెదడుకు

చెందిన ఐదు నెలల బాబు చురుగ్గా లేకపోవడం, ఎప్పుడూ కిందికే చూస్తుండటం, మధ్యమధ్యలో ఫిట్స్ కూడా పస్తుండటంతో వాళ్ల తల్లిదండ్రులు కిమ్స్ ఆస్పత్రికి తీసుకొచ్చారు. పరీక్షించగా, మెదడులో సమస్య ఉన్నట్లు తెలిసింది. వయసు ఐదు నెలలే అయినా, సమస్య తీవ్రత దృష్ట్యా శస్త్రచికిత్స చేయాలని నిర్ణయించాం. చిన్నవయసు కావడంతో అత్యంత సున్నితంగా, జాగ్రత్తగా శస్త్రచికిత్స చేసి, యాజ్ఞెస్సు ఫూర్తిగా తొలగించాం. దాంతో బాబుకు కాళ్ళు, చేతులు పనిచేయడం మొదలైంది, చూపు కూడా సాధారణ స్థితికి చేరుకుంది. ఫిట్స్ సమస్య కూడా కొంతవరకు తగ్గింది. అయితే, మరికొంత కాలం పాటు ఫిట్స్ మందులు వాడాలి అని వివరించారు. అనంతపురం ప్రాంతంలో ఐదు నెలల వయసున్న బాబుకు మెదడు

మూత్రకోశంలో కేన్సర్ వచ్చిన మహిళకు కిమ్స్ సవీరా ఆస్పత్రిలో శస్త్రచికిత్స

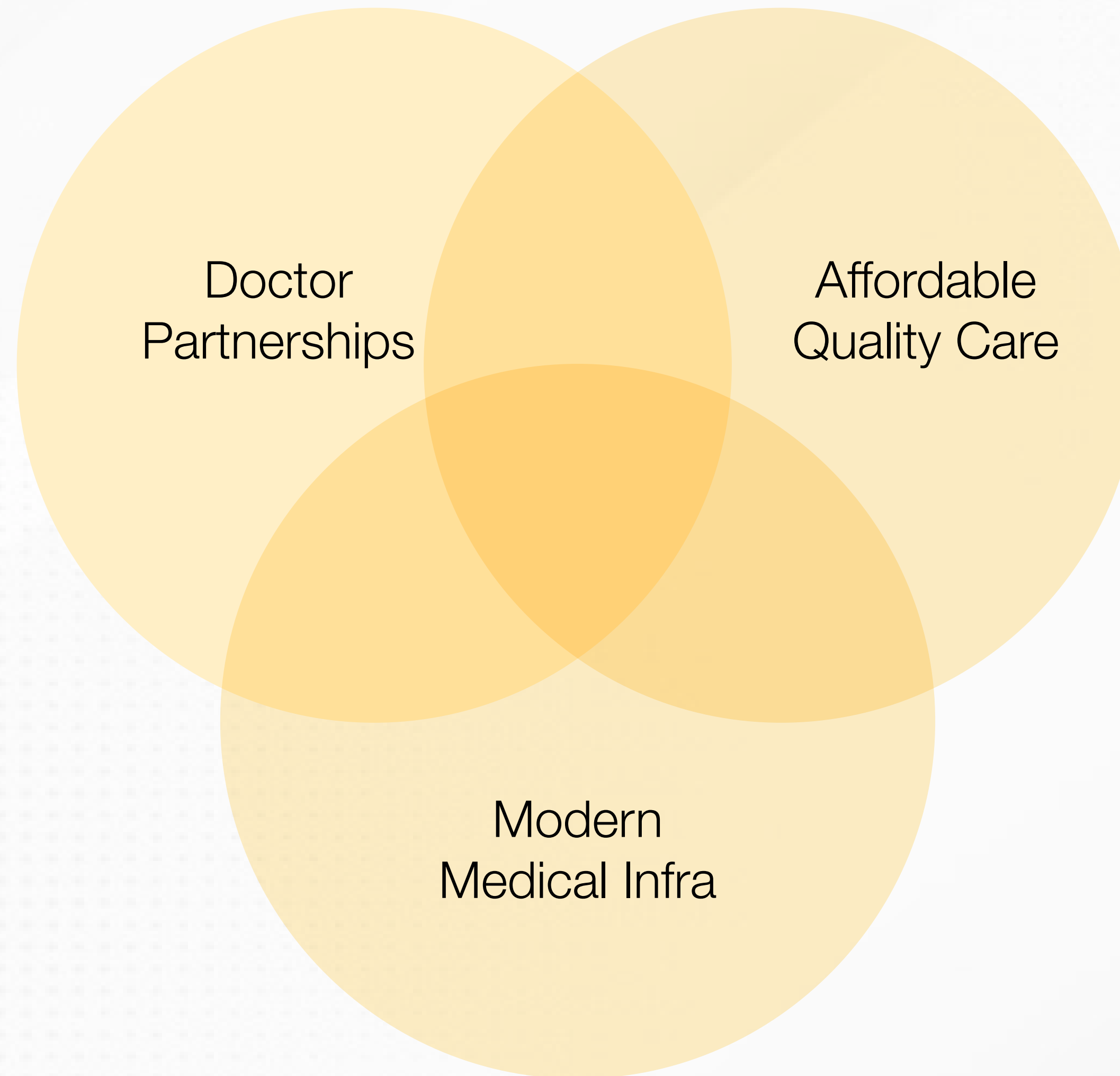
సంక్లిష్టమైన చికిత్సను విజయవంతంగా చేసిన వైద్యులు

అనంతపురం, సెప్టెంబర్ 18: నీటి మనదేశం మూత్రకోశంలో కేన్సర్ వచ్చి తీవ్రంగా ఇబ్బంది పడుతున్న ఓ మహిళకు అనంతపురం కిమ్స్ సవీరా ఆస్పత్రి వైద్యులు సంక్లిష్టమైన శస్త్రచికిత్స చేసి ఊరట కల్పించారు. ఈ మహిళ సమస్యను, ఆమెకు చేసిన శస్త్రచికిత్స వివరాలను అనంతపురంలోని కిమ్స్ సవీరా ఆస్పత్రికి చెందిన యూరాలజిస్టు డాక్టర్ దుర్గాప్రసాద్ వివరించారు. అనంతపురం ప్రాంతానికే చెందిన 54 ఏళ్ల ఈ మహిళకు ఎడమవైపు నడుం భాగంలో వివరీతమైన నొప్పి, ఆకలి లేకపోవడం, బరువు బాగా తగ్గడం లాంటి సమస్యలతో తొలుత వేరే ఆస్పత్రులకు వెళ్లారు. రెండుమూడు చోట్లకు తిరిగినా అక్కడ వైద్యులు పెద్ద ఆస్పత్రికి తీసుకెళ్లాలని చెప్పడంతో కిమ్స్ సవీరా ఆస్పత్రికి వచ్చారు. ఇక్కడ పరీక్షలు చేయగా, మూత్రపిండా లో పొట... మూత్రకోశం కూడా బాగా చాపు వచ్చింది. పరీక్షలు చేయగా ఆమెకు మూత్రకోశ కేన్సర్ వచ్చినట్లు తెలిసింది. దాంతో ఆమెకు నెఫ్రోయూరోలొజీకి శస్త్రచికిత్స చేసి ఖైదర్ కఫ్ తీసేశాం. శస్త్రచికిత్సకు దాదాపు 6 గంటల సమయం వచ్చింది. కేన్సర్ కటితి మొత్తాన్ని ఫూర్తిగా తొలగించాం. శస్త్రచికిత్స చేసిన



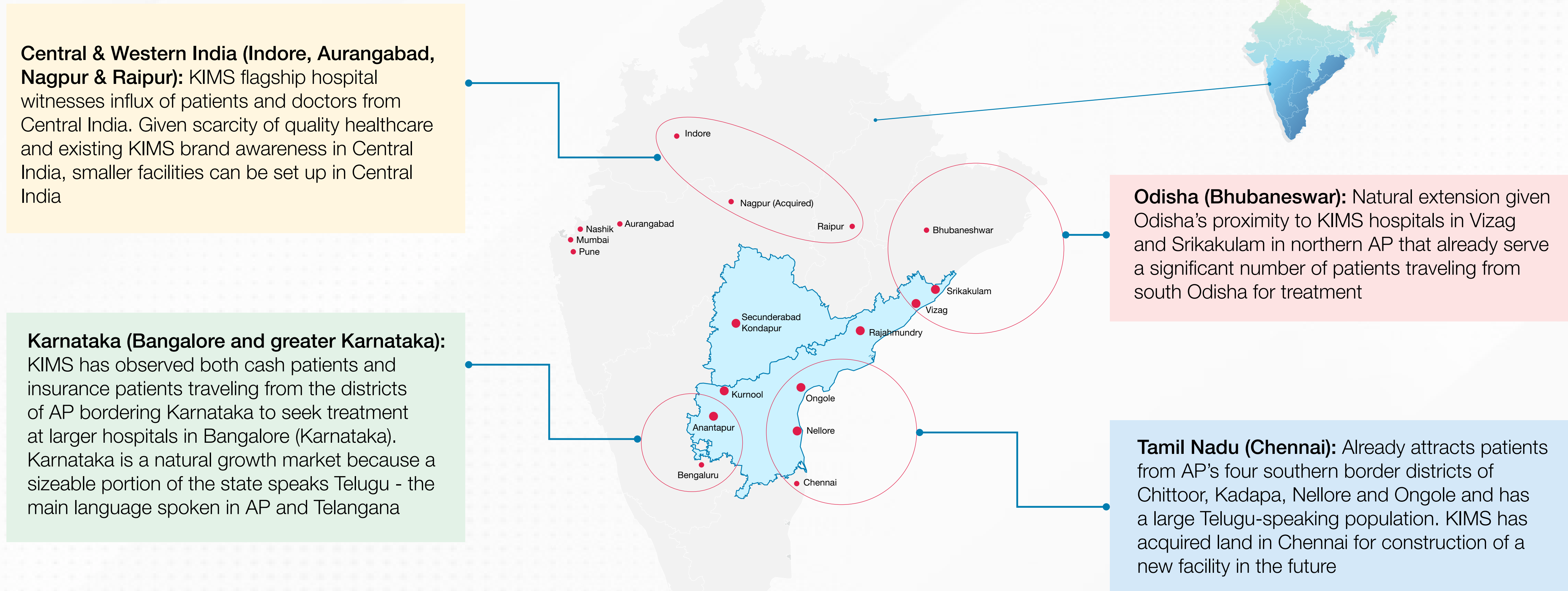తరం జాగ్రత్తగా ఉండి ఎప్పుడీకప్పుడు పరీక్షలు చేసుకోవాలి. గతంలో ఇలాంటి సంక్లిష్టమైన శస్త్రచికిత్సలు హైదరాబాద్, బెంగళూరు లాంటి

Key to our success



Kims has a disciplined growth strategy - strategically grow in adjacent markets some of which are 'natural extensions'

KIMS Plans to Grow into Markets that are Adjacent to the Current Core Markets of AP and Telangana



Update on Expansion Plans

Future vision taking shape - Construction update



**KIMS-SUNSHINE
BEGUMPET**



**KIMS HOSPITALS
BANGALORE**



**KIMS-MANAVATA
NASHIK**



**KIMS-ICON GASTRO UNIT
VISAKHAPATNAM**

Expansion plans

| Units | Current Beds | Incremental Beds | New Departments | Approx. Capex | Approx. Timeline (Starting April 2021) |
|-------------------------|--------------|------------------|-----------------------------------|---------------|--|
| Kondapur | 200 | 500 | All Specialities | 300 Cr | 36-42 months |
| Vizag | 434 | 50 | Cancer Centre | 15-20 Cr | 36 months |
| Anantapur | 250 | 150 | Cancer Centre / Mother & Child | 50-60 Cr | 36-48 months |
| Ongole | 350 | - | Cancer Centre | 15-20 Cr | 36-42 months |
| Bangalore | - | 350-400 | All Specialities | 300-330 Cr | 36 months |
| Western / Central India | - | 250-300 | All Specialities | 300 Cr | 24-36 months |
| Nashik | - | 325 | All Specialities | 200-250 Cr | 24-36 months |
| Chennai | - | 350-400 | All Specialities | 400 Cr | On hold |

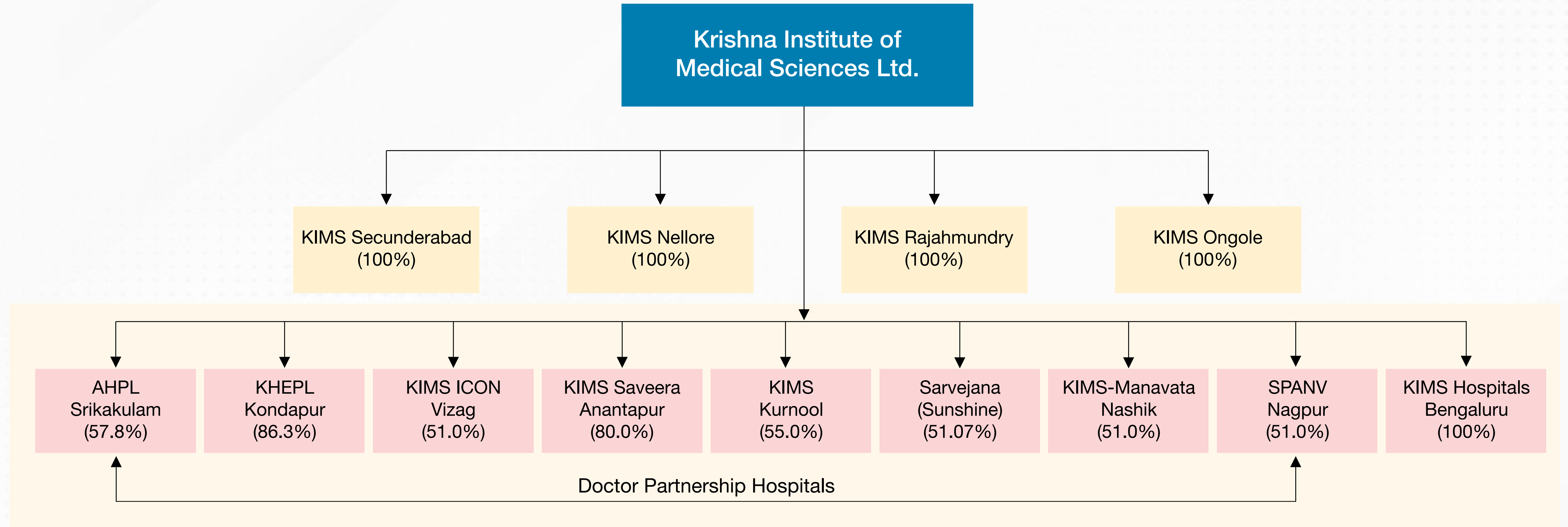
Profit and Loss Statement

(Rupees in Millions)

| Particulars | Q2 FY 23 | Q1 FY 23 | Q2 FY 22 | QoQ(%) | YoY(%) | FY 22 | FY 21 | YoY(%) |
|---------------------------------|----------|----------|----------|--------|--------|--------|--------|--------|
| Operating Revenue | 5,641 | 4,955 | 4,117 | 13.8% | 37.0% | 16,508 | 13,299 | 24.1% |
| Other Income | 92 | 53 | 54 | 72.5% | 70.2% | 203 | 102 | 99.3% |
| Total Revenue | 5,733 | 5,008 | 4,171 | 14.5% | 37.4% | 16,711 | 13,401 | 24.7% |
| EBITDA * | 1,447 | 1,312 | 1,279 | 10.3% | 13.1% | 5,218 | 3,672 | 42.1% |
| EBITDA (%) on operating revenue | 25.7% | 26.5% | 31.1% | -3.1% | -17.4% | 31.6% | 27.6% | 14.5% |
| PBT | 1,226 | 1,074 | 1,132 | 14.2% | 8.4% | 4,569 | 2,790 | 63.7% |
| PBT (%) on total revenue | 21.4% | 21.4% | 27.1% | -0.2% | -21.1% | 27.3% | 20.8% | 31.3% |
| PAT** | 1,061 | 792 | 842.5 | 33.8% | 25.9% | 3,438 | 2,055 | 67.3% |
| PAT (%) on total revenue | 18.5% | 15.8% | 20.2% | 16.9% | -8.4% | 20.6% | 15.3% | 34.2% |
| Basic EPS (Rs.) | 12.1 | 8.7 | 10.3 | 38.9% | 17.4% | 41.9 | 26.9 | 55.9% |
| Diluted EPS (Rs.) | 12.1 | 8.7 | 10.3 | 38.9% | 17.4% | 41.9 | 26.4 | 58.5% |
| | | | | | | | | |
| IND AS 116 | 77 | 59 | 9 | | | 35 | 37 | |

*EBITDA before IND AS 116 and other income

**PAT is including fair value gain on aquisition of control amounting to INR 148.3 Mn for Q2 FY23



Thank You