



East Buildtech Limited

(Formerly known as Chokhani Business Limited)

Regd. Office :
'CHOKHANI HOUSE'
D-3/2 Okhla Industrial Area, Phase-II,
New Delhi -110020 (INDIA)
Tel. : +91-11-26389150, 26384122
Fax. : +91-11-41615273
E-mail : contact@chokhani.in
CIN : L74999DL1984PLC018610

Date: 03.05.2024

To
The General Manager
Corporate Relationship Department
BSE Ltd.
Phiroze Jeejebhoy Towers, Dalal Street
Mumbai -400 001

BSE SCRIP CODE: 507917

SUB: INTIMATION IN RELATION TO RESIGNATION OF INDEPENDENT WOMEN DIRECTOR WITH EFFECT FROM 09TH APRIL, 2024

This is to inform you that that the second term of office of Mrs. Lakshmi Devi Chokhani as Independent Women Director expired on April 10, 2024. This information was duly intimated to Mrs. Chokhani by our company.

Unfortunately, Mrs. Chokhani was hospitalized for cancer treatment, which led to a delay in the submission of her resignation letter. The resignation letter was received by the company on May 3, 2024, due to these unforeseen circumstances.

Attached to this letter is a medical summary of Mrs. Chokhani's condition for your reference. Further we sincerely apologize for the delay in submitting the compliance report as per Regulation 30 of the Securities and Exchange Board of India (Listing Obligations and Disclosure Requirements) Regulations, 2015. The delay was caused by the additional time required to complete formalities, including the processing of Mrs. Chokhani's resignation.

Please find attached Mrs. Lakshmi Devi Chokhani's resignation letter, which has been duly accepted by the management of our company. We kindly request you to take this into your records.

We assure you that we have implemented measures to prevent such delays in the future. We understand the importance of timely disclosures and regret any inconvenience this may have caused.

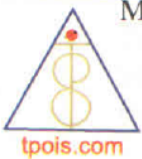Please consider and accept it.

Sincerely,

For East Buildtech Limited

Chetan Goel
(Company Secretary)

M. No. A28069



Think Positive on Industrial Surplus

Sell Industrial Surplus & Products

(T&C apply)

Date: 09.04.2024

To,

The Board of Directors,

East Buildtech Limited

D-3/2, Okhla Industrial Area,
Phase-II New Delhi-110020

Sub: Resignation from the position of Director

Dear Sir/Madam,

Due to personal and unavoidable circumstances, I hereby tender my resignation from the Directorship of the Company with immediate effect. Kindly accept this letter as my resignation with immediate effect, from the post of Director of **EAST BUILDTECH LIMITED**, and relieve me of my duties. Kindly acknowledge the receipt of this resignation letter and arrange to submit the necessary forms with the office of the Registrar of Companies to that effect.

Thanking You

Yours sincerely,

Lakshmi Chokhani

(LAKSHMI CHOKHANI)

SDIN: 01060489

Resignation Accepted

[Signature]

SURESH KUMAR GOENKA
DIRECTOR

(DIN: 01137986)



Breast Clinic

Lakshmi Chokhani
Patient Id: 20170711162

Female, 71 Years

By: **Dr. Saranyasri S R**

Registration Number: 136344

Clinical Notes

Date: **9 Jun, 2023**

Complaint

- Referred with 3 weeks history of painful lump in right breast. No previous breast problems or screening mammography done

Observation

- RISK FACTORS FOR BREAST CANCER:** There is no family history of breast cancer. Age of menarche - 14 years. Age of surgical menopause - 52 years. No of children - 3: Age- 51,45 &40 years; Breast fed for 8 months

PAST MEDICAL HISTORY: 1) Hypertension- 12 years 2) Paraumbilical Hernia- Awaiting surgery 3) Osteoarthritis Right Knee- 2006 4) Hysterectomy 5) Cholecystectomy

DRUG HISTORY: T.Telma AM 1-0-0. No history of drug allergies.

CLINICAL EXAMINATION: Breast examination showed 3.5cm palpable lump in right breast 2 o'clock 3cm from the nipple suggestive of Malignant lump (P6). Left breast felt completely normal with no discrete lumps to feel (P1). There was no palpable axillary or supraclavicular lymphadenopathy.

Investigations


- MAMMOGRAM:** Bilateral mammogram showed scattered fibroglandular breast tissue (Type 1 Tabar pattern) with 3cm irregular spiculated mass lesion in the upper inner aspect of the right breast involving Pectoralis major muscle suggestive of Malignant lesion (BIRADS M5).
- ULTRASOUND BREASTS:** Bilateral breast ultrasound scan showed a 31.7mm x 23.2mm hypochoic homogenous lesion in the right breast 2 o'clock position 3cm from the nipple suggestive of Malignant Lump(U6). Right axillary ultrasound showed 24.4 x 16.1mm oval lesion suggestive of Involved node. Left breast ultrasound showed no significant abnormality. Left Axillary ultrasound showed 24.4 x 10mm hypochoic oval lesion suggestive of Enlarged Axillary node
- PROCEDURE:** After informed consent, she has had ultrasound guided core biopsies from the right breast lump under local anaesthetic
- HISTOPATHOLOGY:** Core biopsies from left breast lump have confirmed Grade 2 Invasive ductal carcinoma (B5). ER, PR and Her2 has been requested on the core biopsy sample
- STAGING INVESTIGATIONS:** A Staging PET CT showed Irregular hypermetabolic mass in upper inner quadrant of right breast with infiltration of Pectoralis major muscle with Level 1 Right Axillary and Right Internal Mammary nodes suggestive of Lymphnode metastasis. Enlarged and Hypermetabolic left axillary, left supraclavicular, paratracheal and left hilar lymphnodes - ?Granulomatous/? Distant lymphnode Metastasis. Metabolic nodule in left adrenal - Probably Adenoma with no evidence of metastasis to lung, liver or bone.
- LEFT AXILLARY NODE CORE BIOPSY:** She underwent ultrasound guided left axillary node biopsy which confirmed Granulomatous lymphadenitis. (B2).





Breast Clinic

-
- Diagnosis
- Right breast Grade 2 Invasive ductal carcinoma with involved right axillary & Internal mammary node. Left axillary Granulomatous lymphadenitis.
-
- Notes
- PLAN: She has been counselled regarding the diagnosis and staging and been advised to undergo Neoadjuvant chemotherapy with 4 cycles followed by surgery (Right mastectomy and axillary clearance). ER, PR and Her2 results are awaited and she needs to be referred to the medical oncologist urgently. Routine blood tests, ECG Echocardiogram, Chest Xray requested. Commenced on AKT4 and T.Benadone 40mg od for 2 months followed by AKT2 for 4 months for Granulomatous lymphadenitis.
 - -----
 - Thanks for the referral, Dr Arun and Dr Sriram
-


Dr.N.Suresh Anand
MS (Gen.Surgery),FRCS (Edin),FRCS (Gen.Surgery & Breast)
Consultant Breast & Oncoplastic Surgeon

Dr. N. SURESH ANAND
M.S. (Gen.Surg) FRCS (Edin),
FRCS (Gen.Surg & Breast)
Consultant Breast & Oncoplastic Surgeon
TN Medical Council Reg No. 48500

